



МЕДИЦИНСКИ УНИВЕРСИТЕТ – ПЛОВДИВ
ФАКУЛТЕТ „ЗДРАВНИ ГРИЖИ“
ЦЕНТЪР ЗА ДИСТАНЦИОННО ОБУЧЕНИЕ

Лекция №3

Част втора
Спешни очни заболявания

ПРОФ. Д-Р ЧАВДАР БАЛАБАНОВ, Д.М.

ТРАВМИ

- КОНТУЗИОННИ (“ ”):

-

- НАРАНЯВАННЯ:

-

-

-

vulnus punctum

vulnus scissum

vulnus lacerocontusum (

)

-

КЛАСИФИКАЦИЯ (ПО СТРУКТУРИ)

ОРБИТА И ОЧНИ ПРИДАТЪЦИ

- _____
- _____
-
-

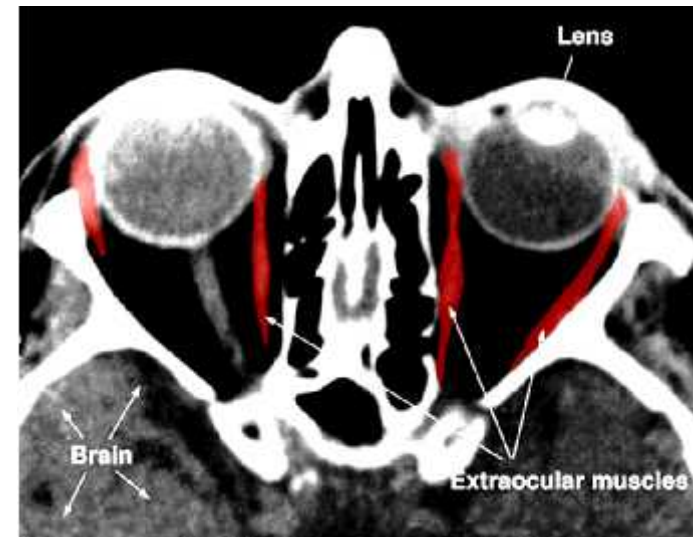
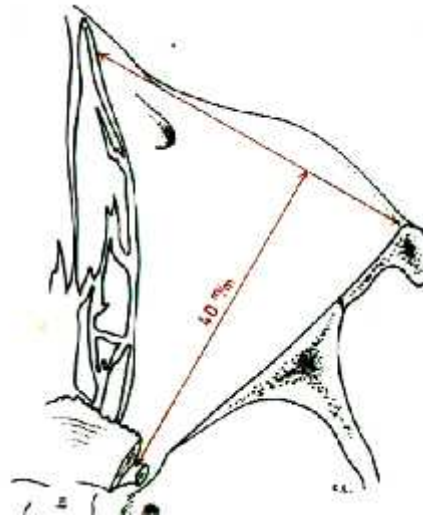
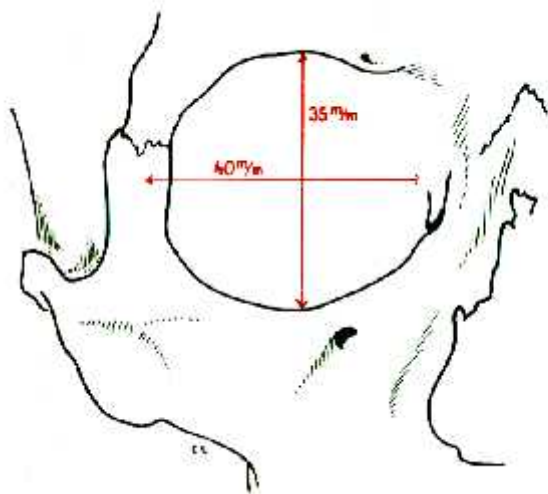
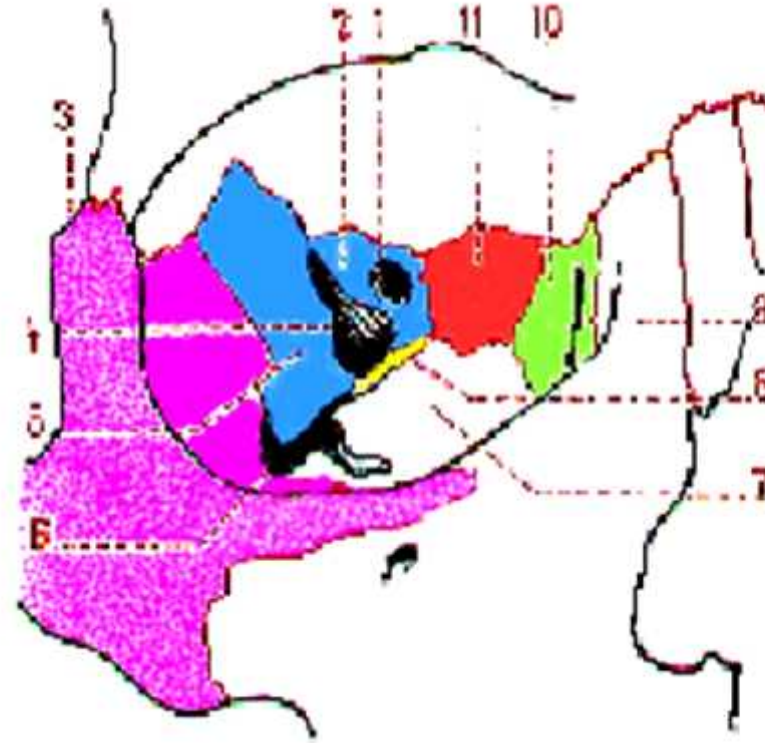ОЧНА ЯБЪЛКА

- (_____ , _____ , _____)
- (_____ , _____)

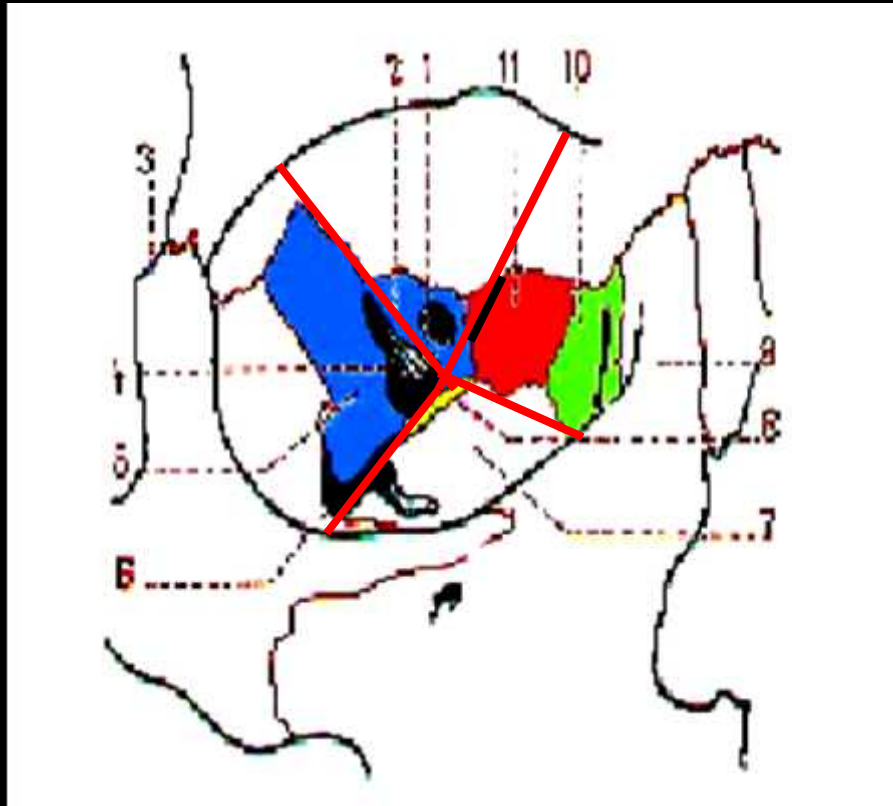
ОРБИТА И ПРИДАТЪЦИ

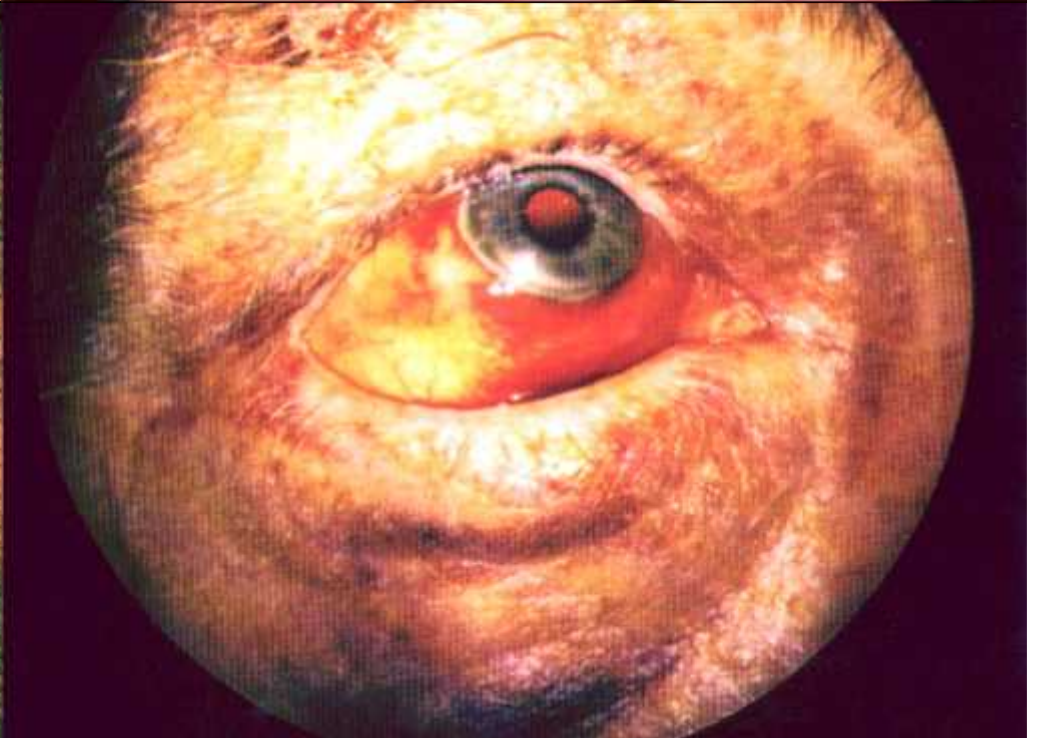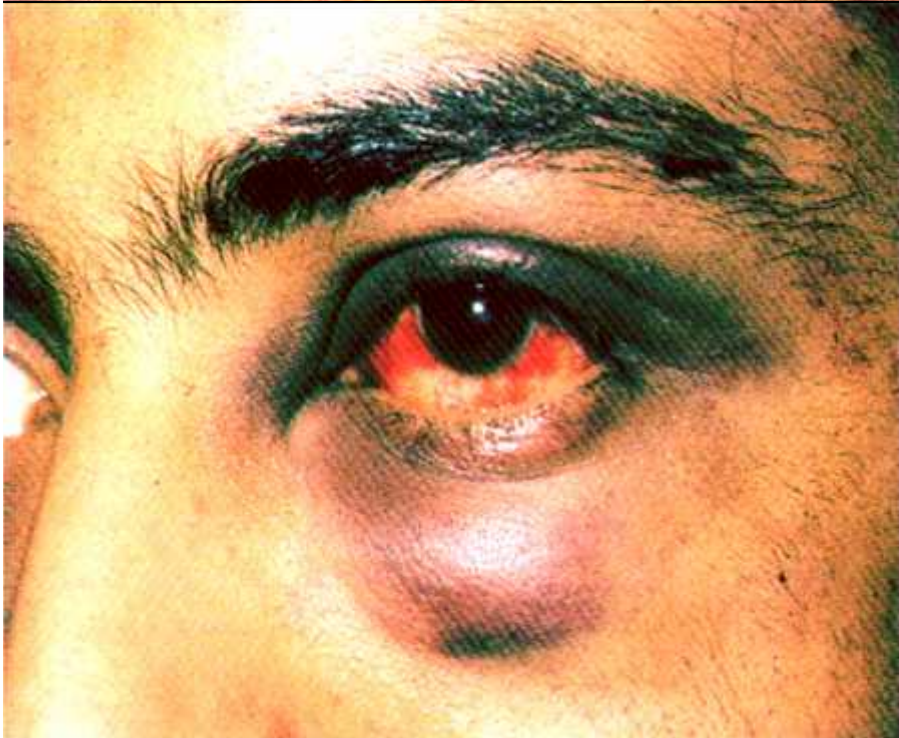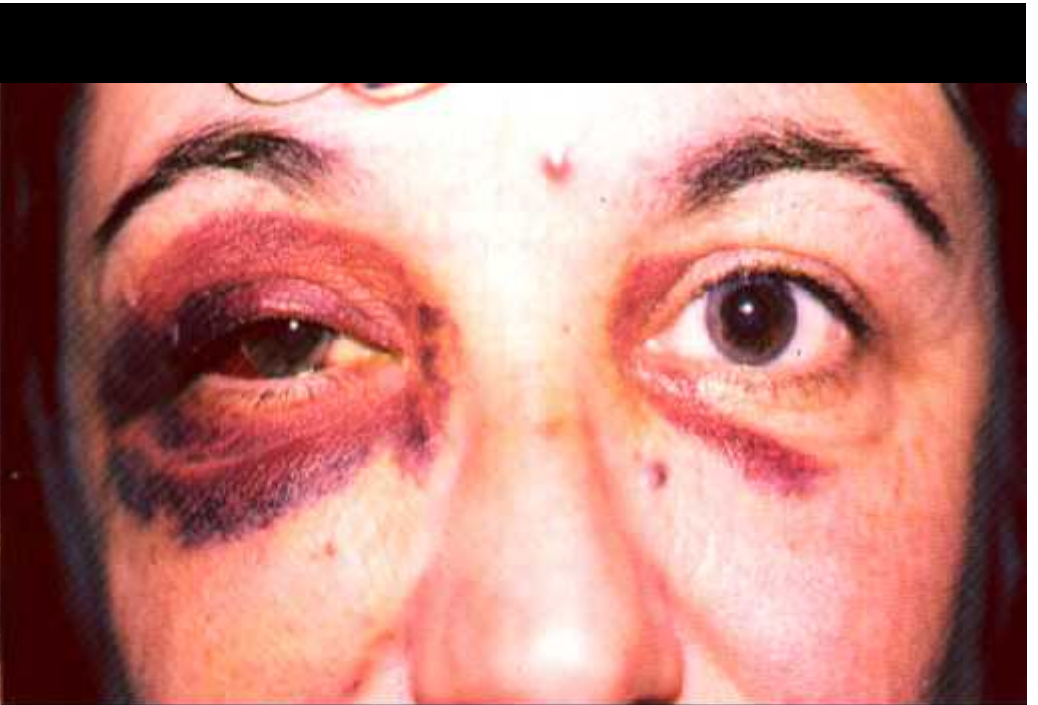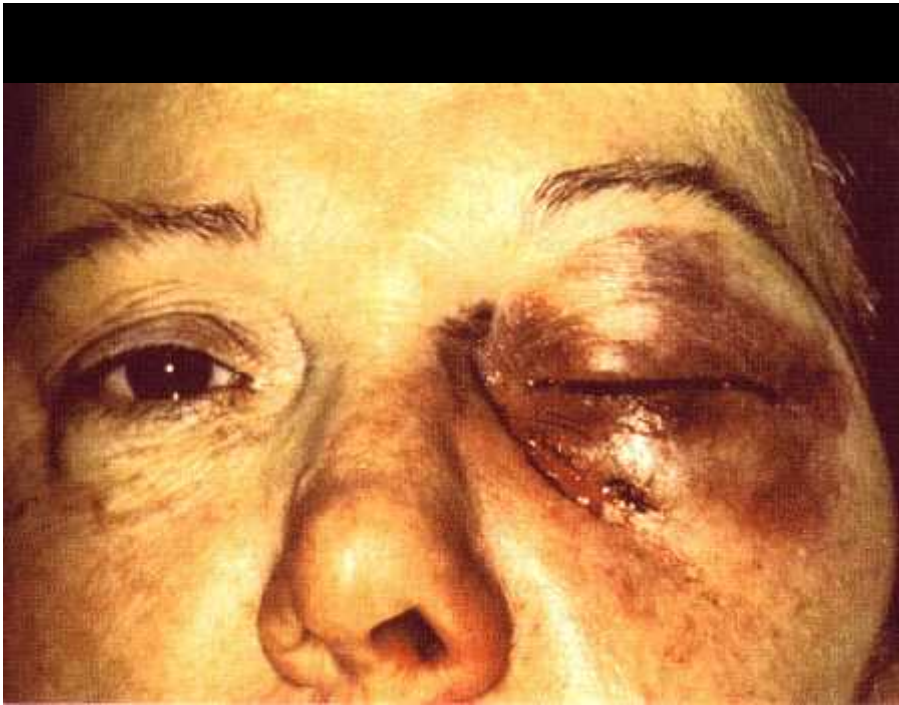ОРБИТА

- **os sphenoidale**
 - ala major (5)
 - ala minor (2)
- **os zygomaticum** (3)
- **os maxillare** (7)
- **os palatinum** (8)
- **os lacrimale** (10)
- **os ethmoidale** (11)
- **os frontale** (12)

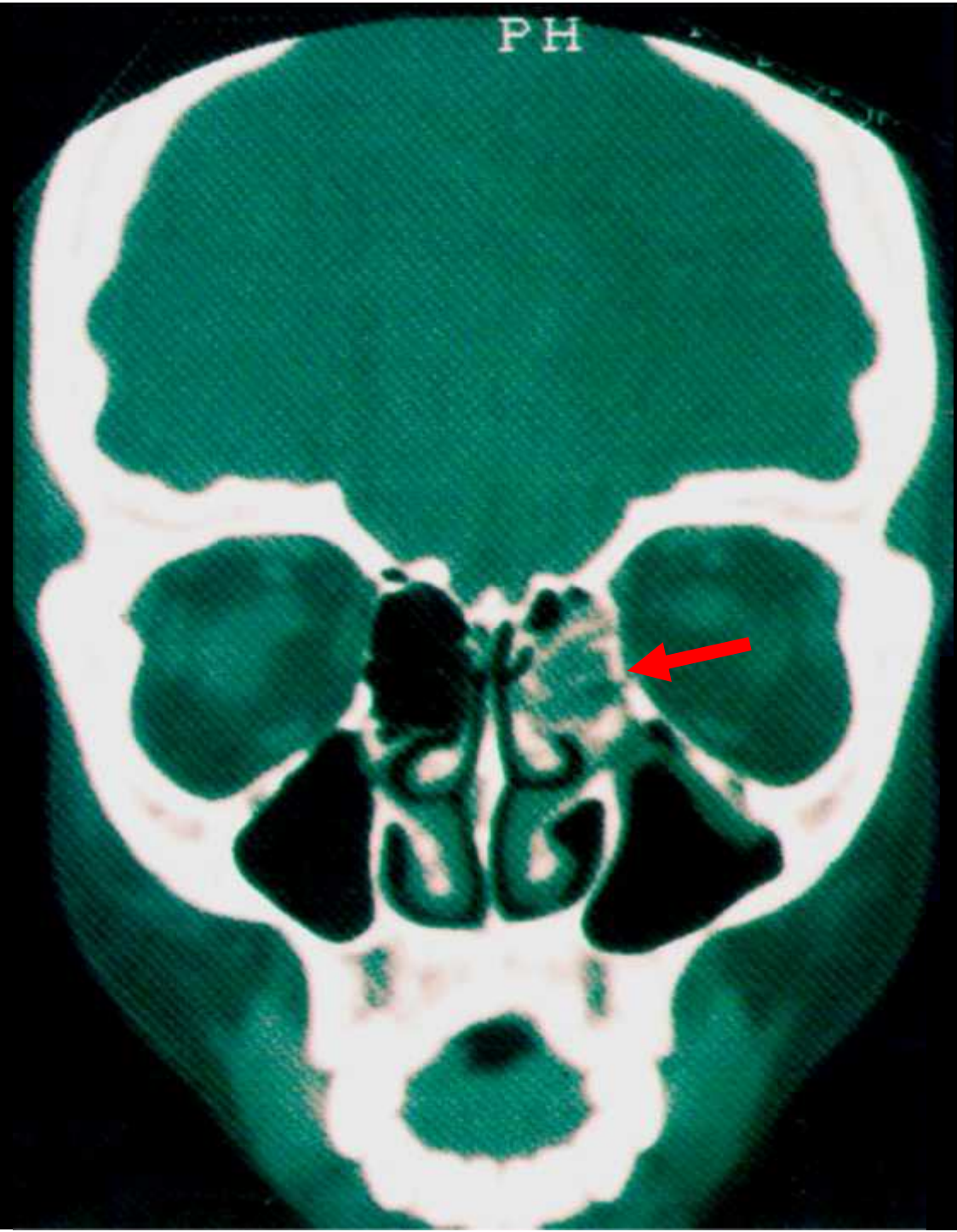


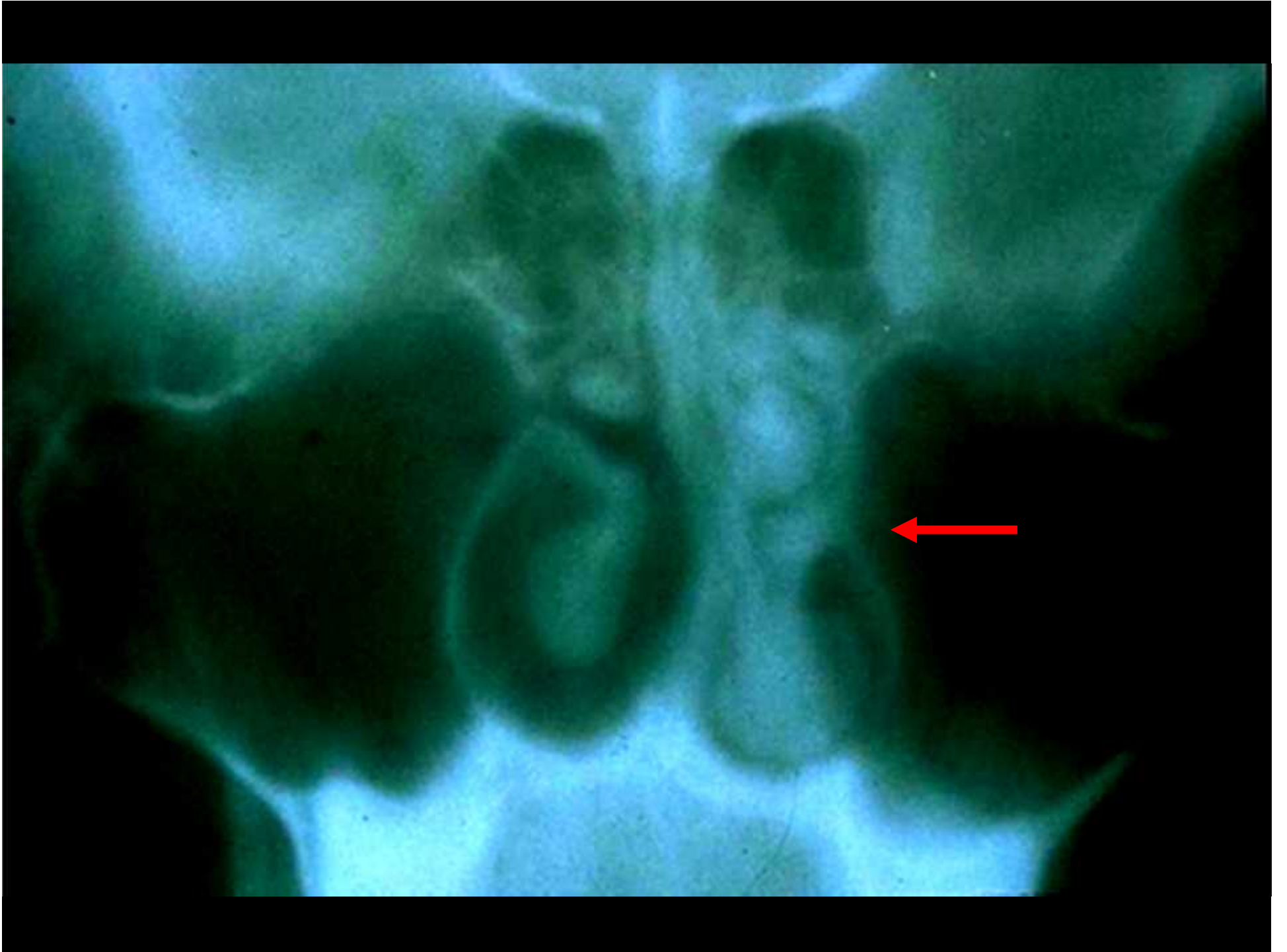
ДИРЕКТНИ ТРАВМИ НА ОРБИТАТА

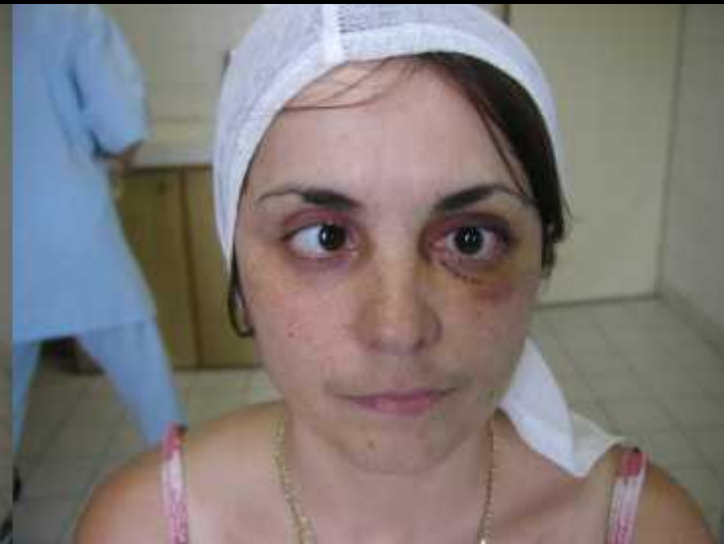
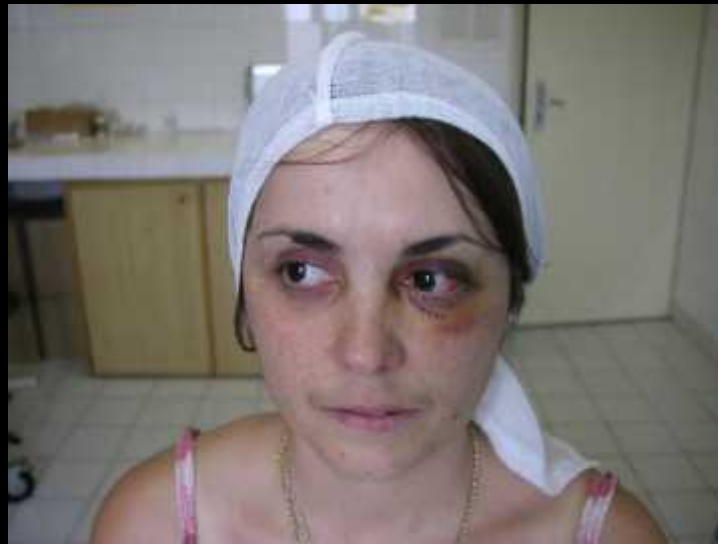
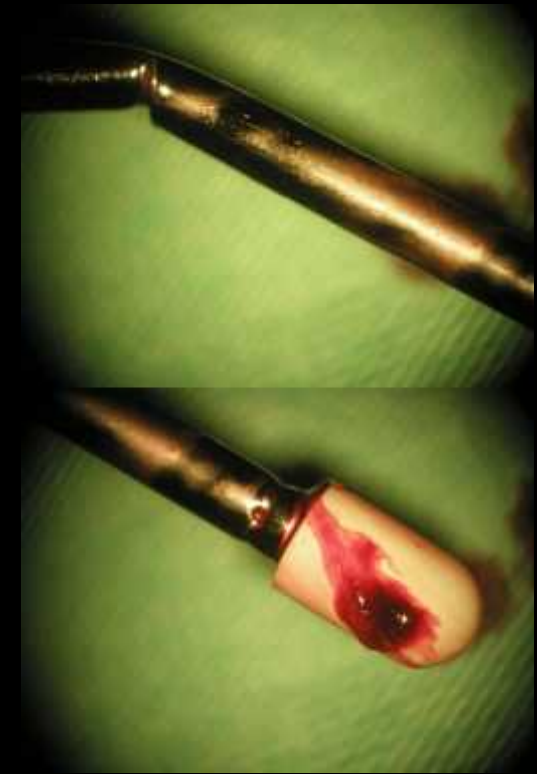
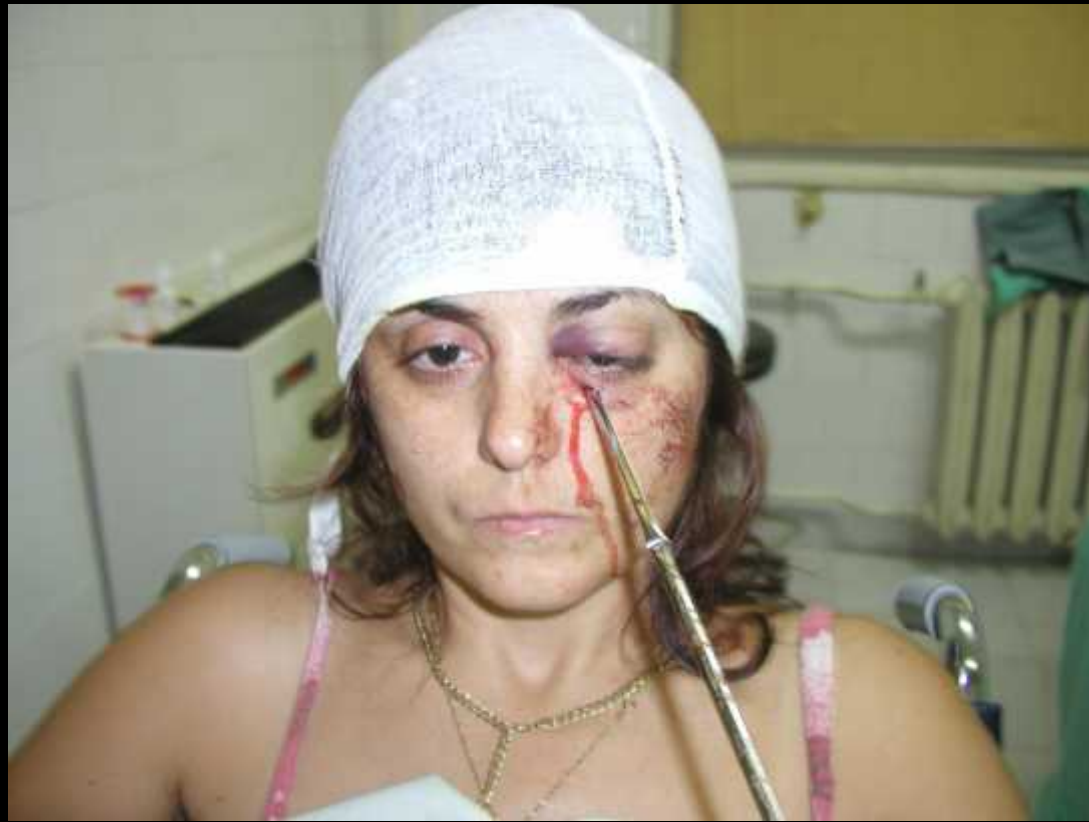
PH



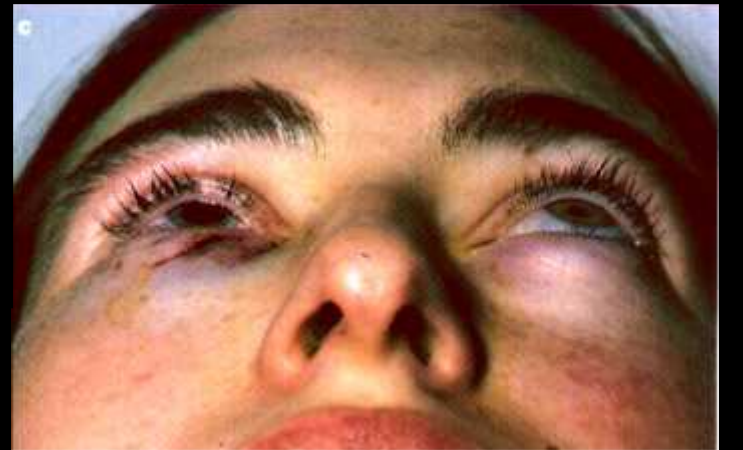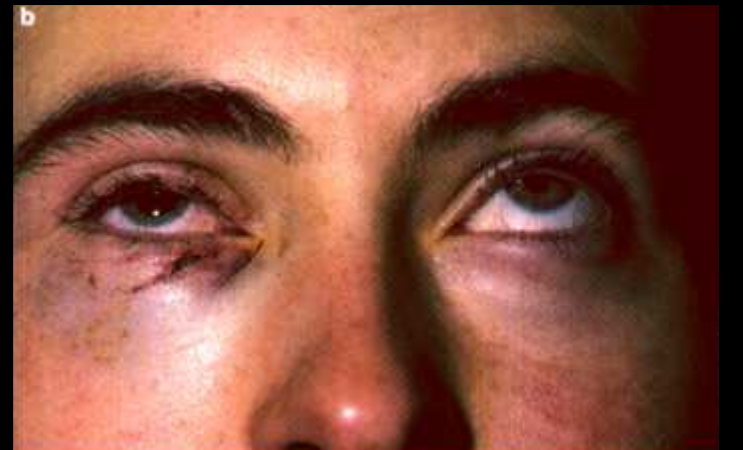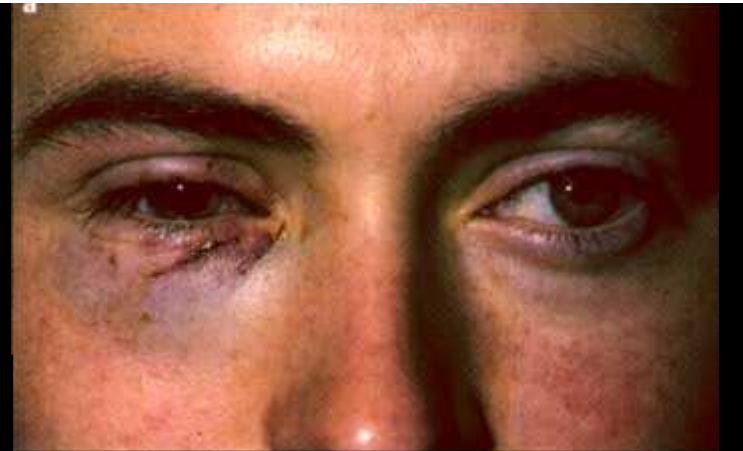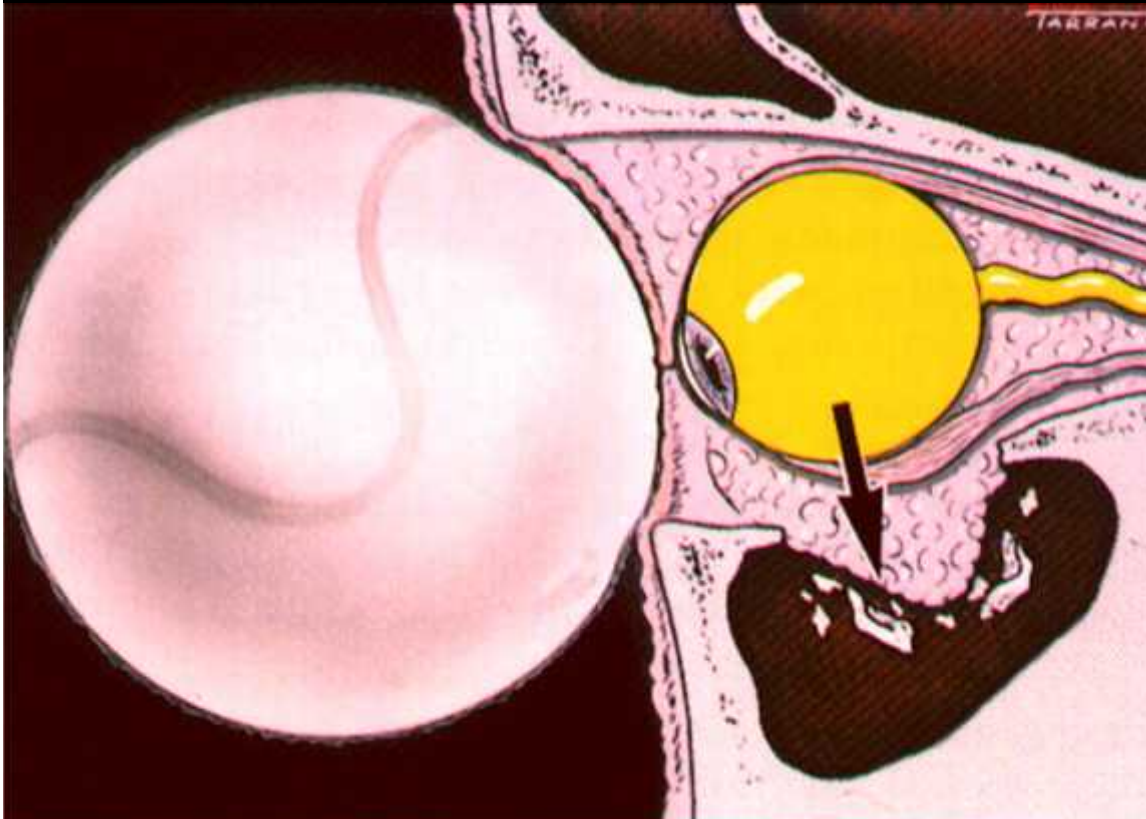




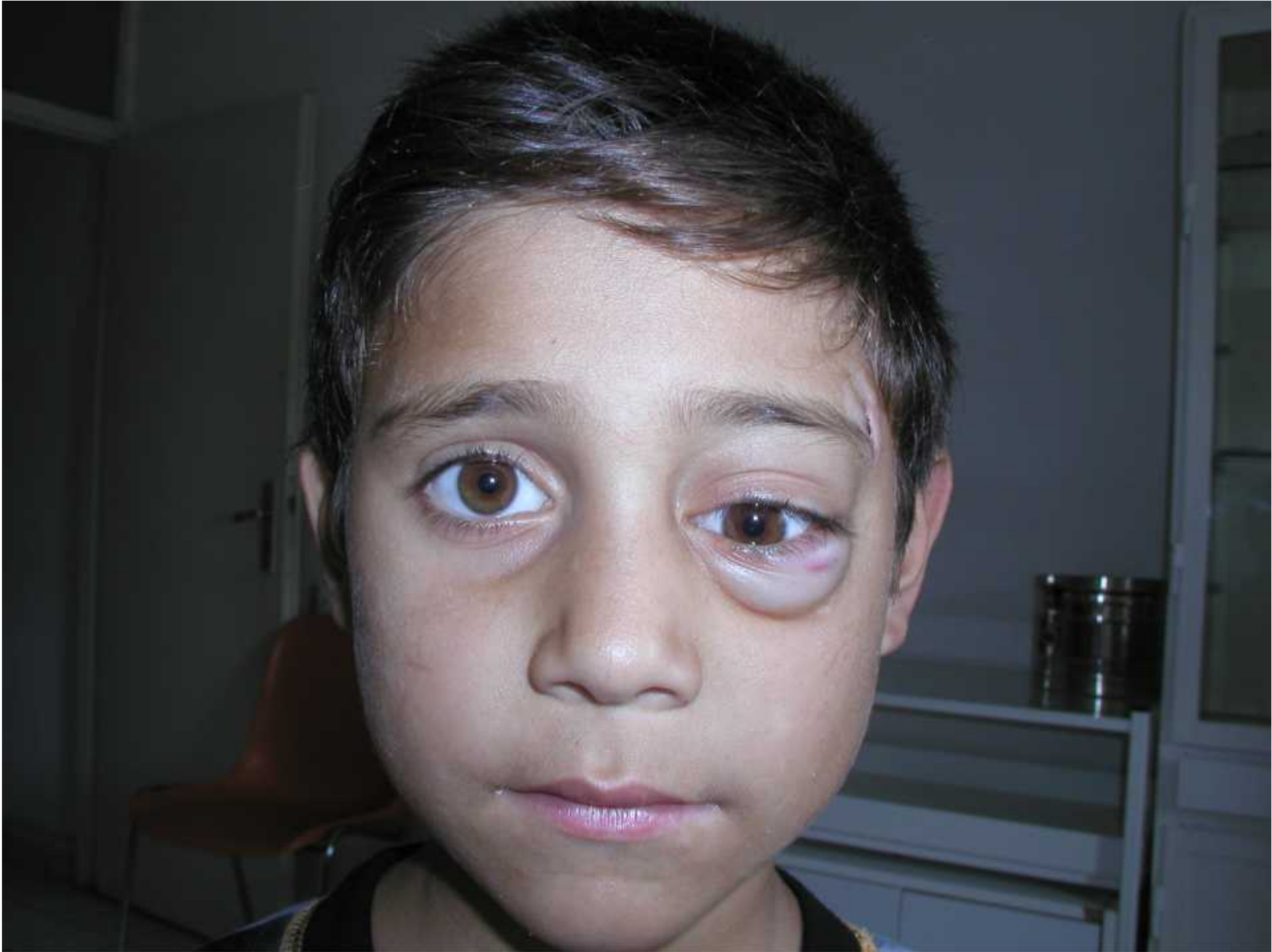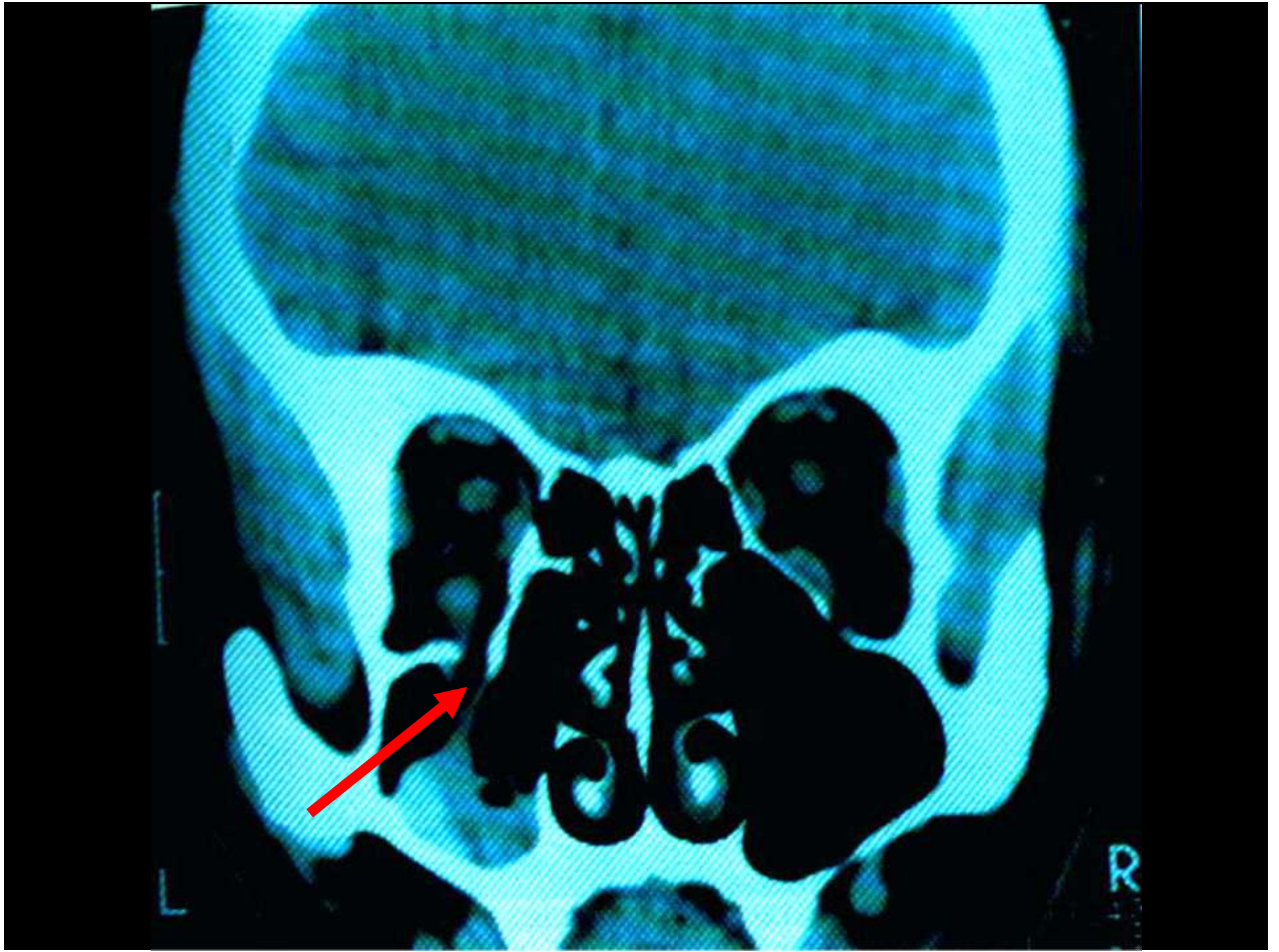
ИНДИРЕКТНИ ТРАВМИ НА ОРБИТАТА

BLOW-OUT FRACTURE

()



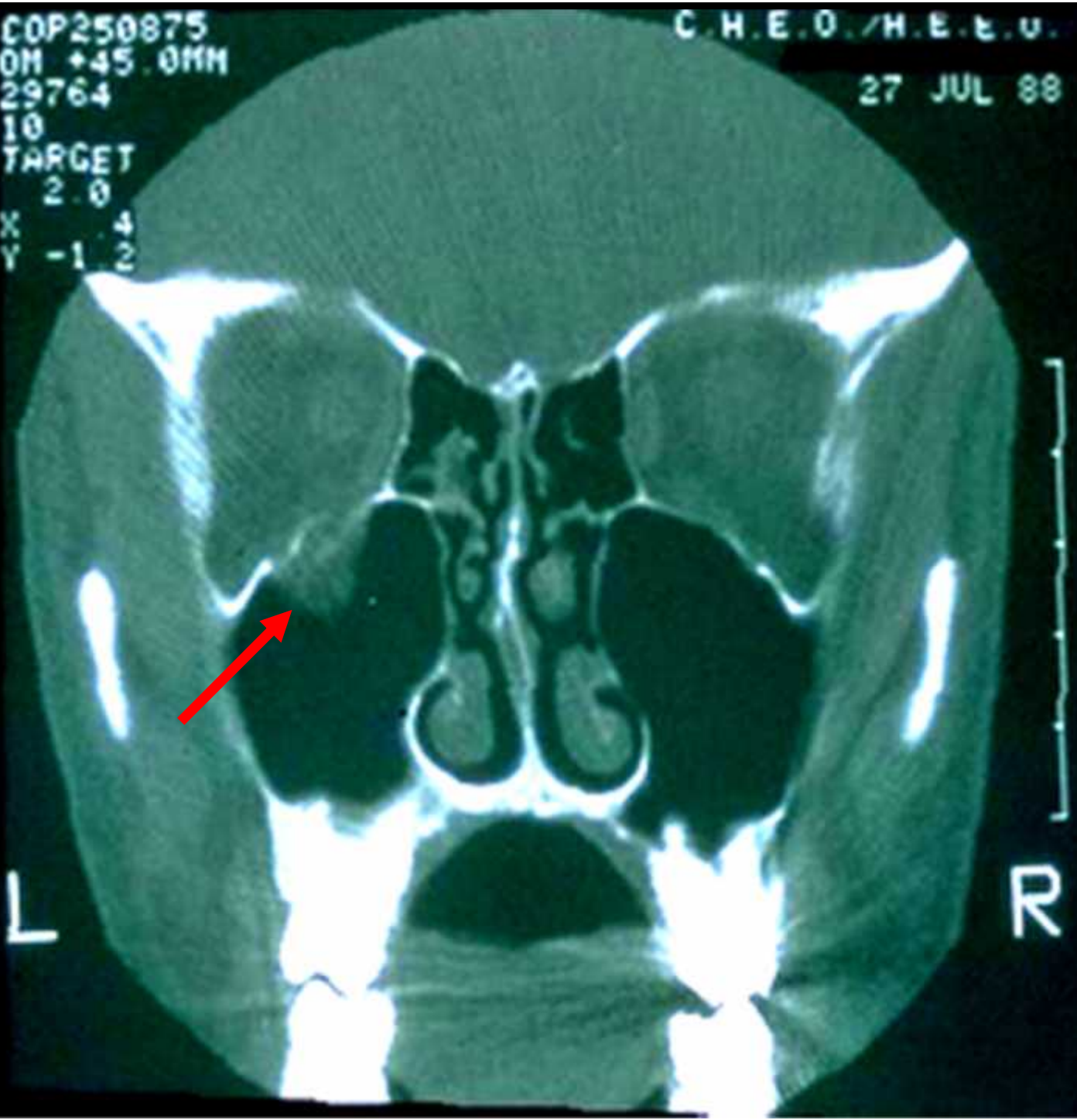




COP250875
OM +45.0MM
29764
10
TARGET
2.0
X 4
Y -1.2

C.H.E.O./H.E.E.U.

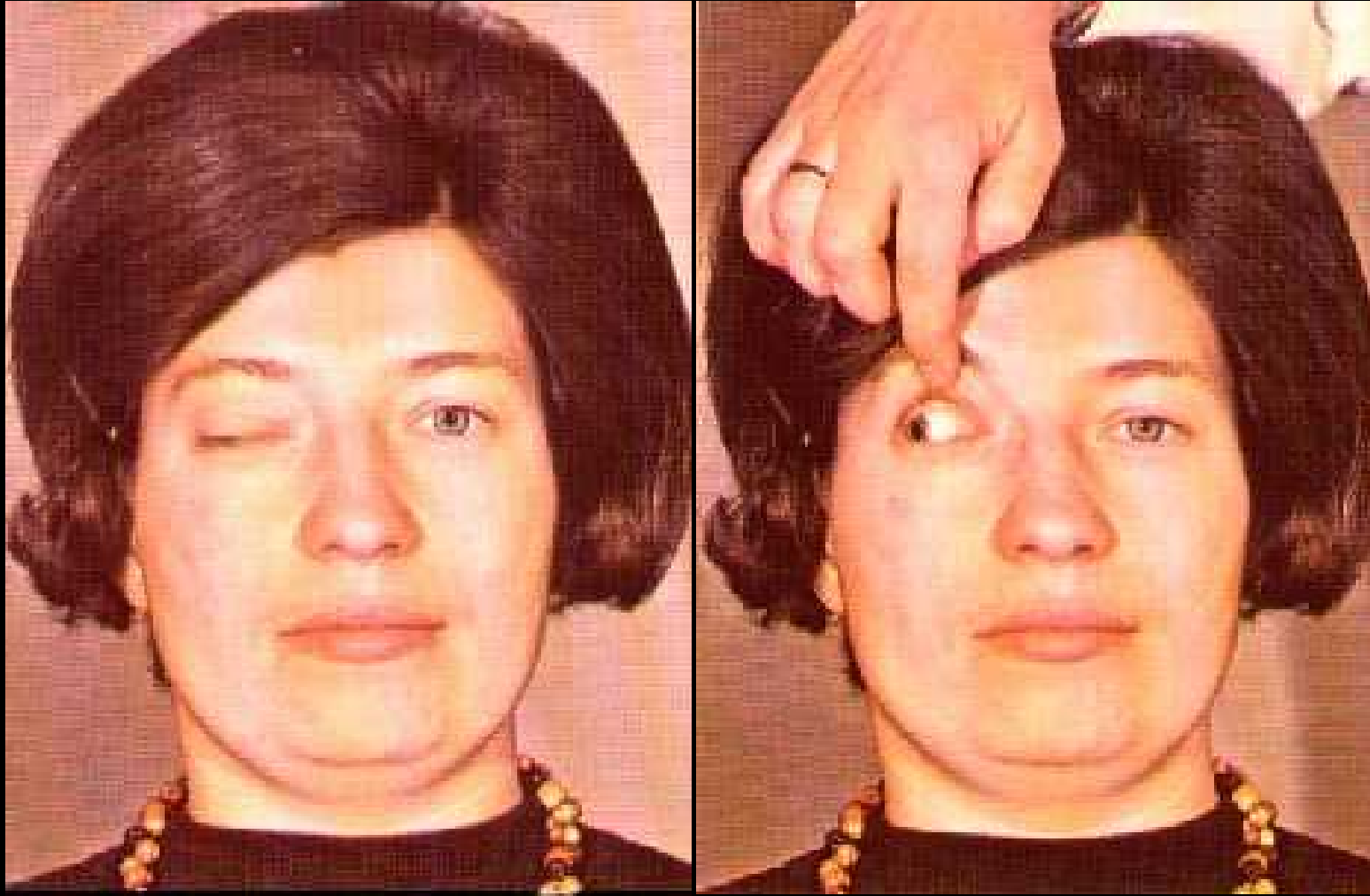27 JUL 88



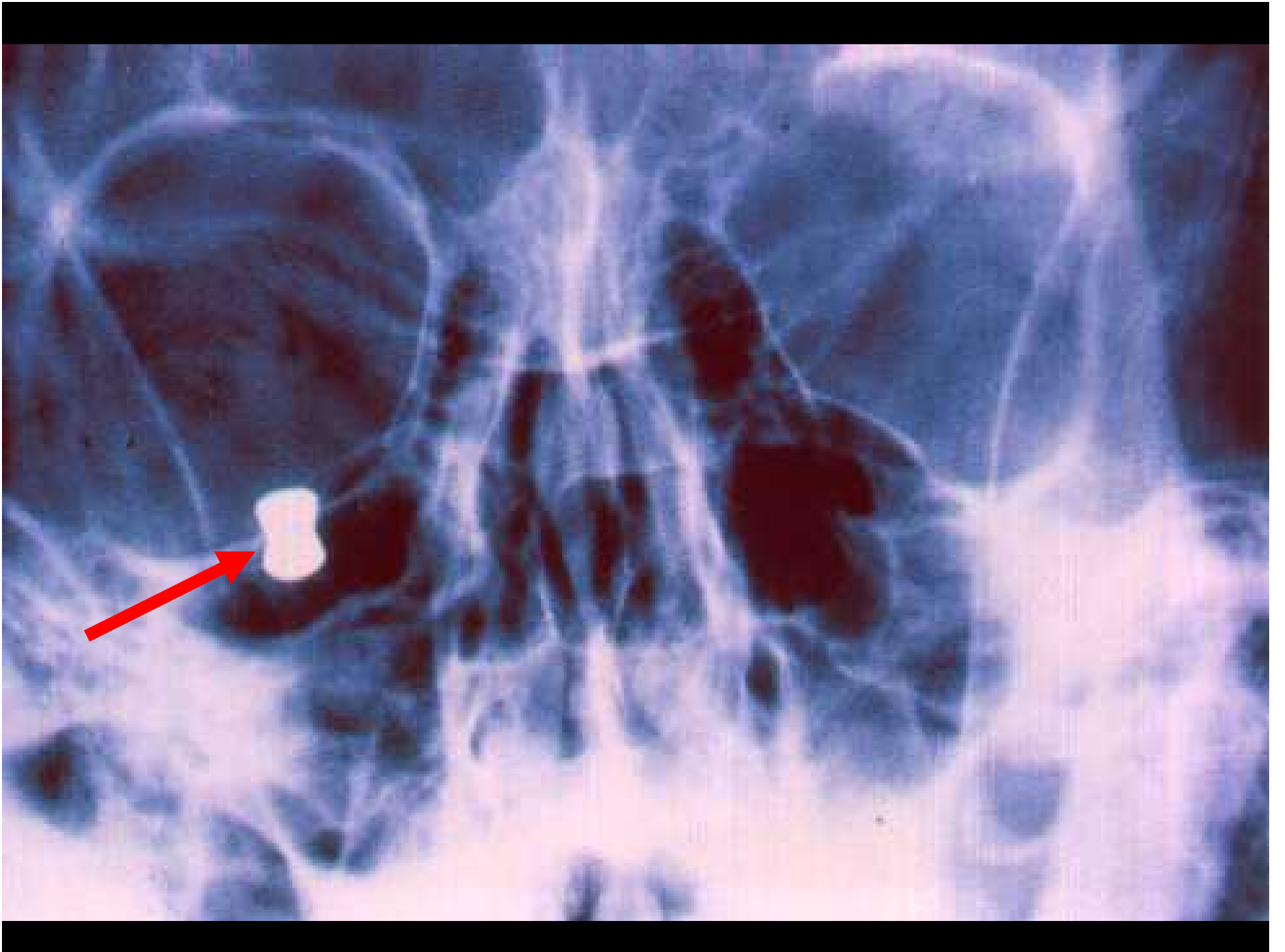
L

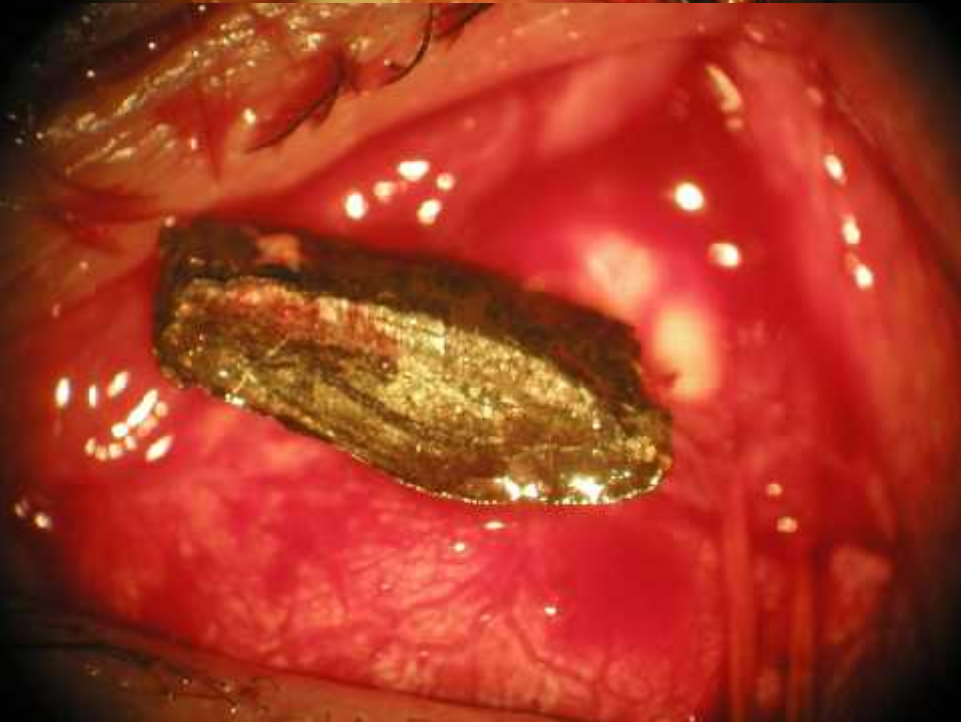
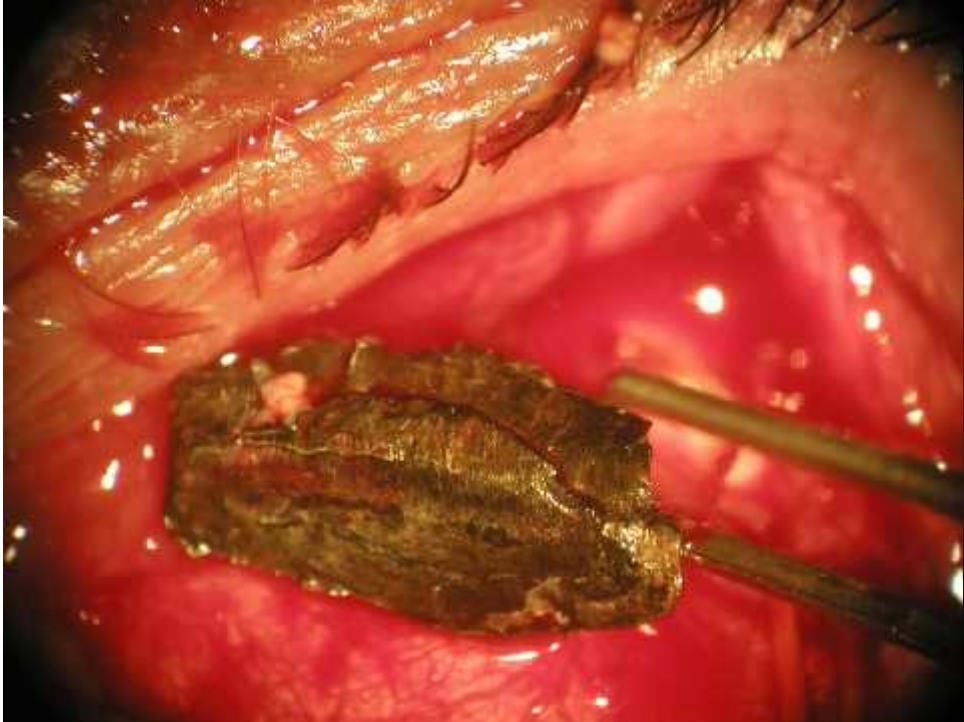
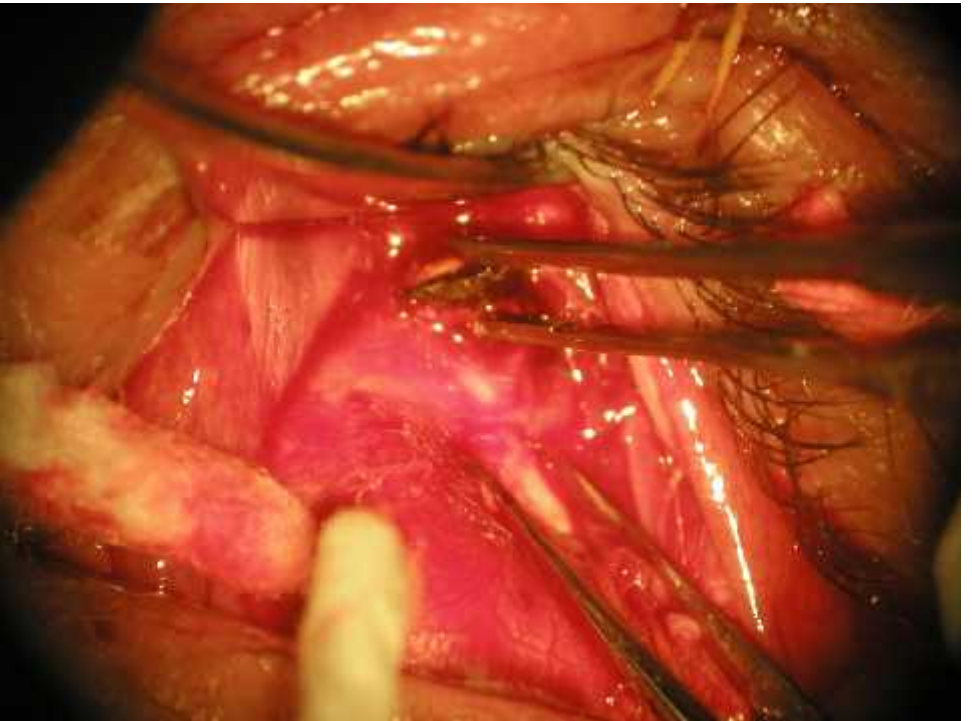
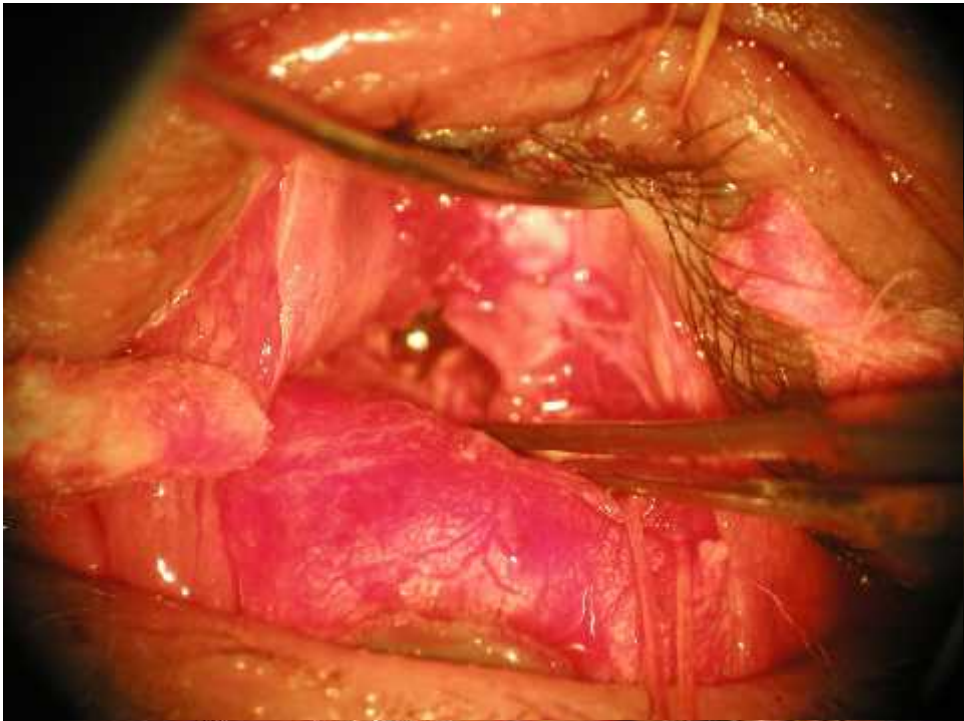
R

Засягане на n. oculomotorius



ЧУЖДИ ТЕЛА В ОРБИТАТА





ПЛАН ЗА ПЪРВА ПОМОЩ

1.

:

- commotio cerebri? (mannitol,)

- (!!!)

- ()

- (!!)

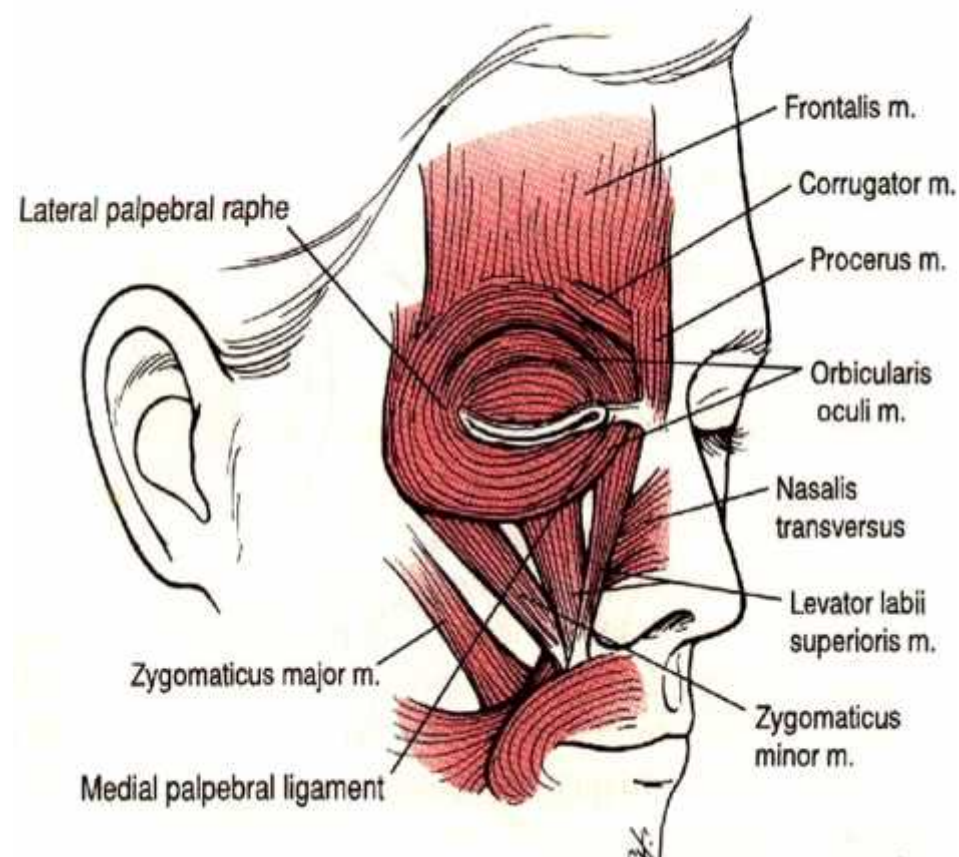
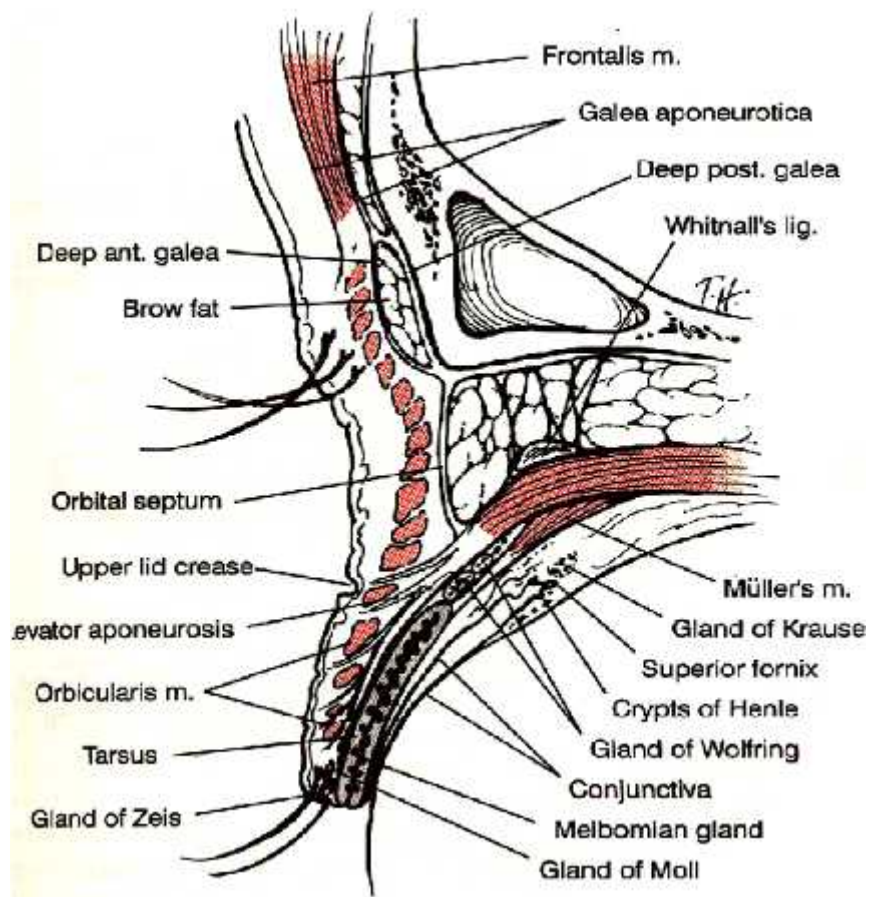
-

2.

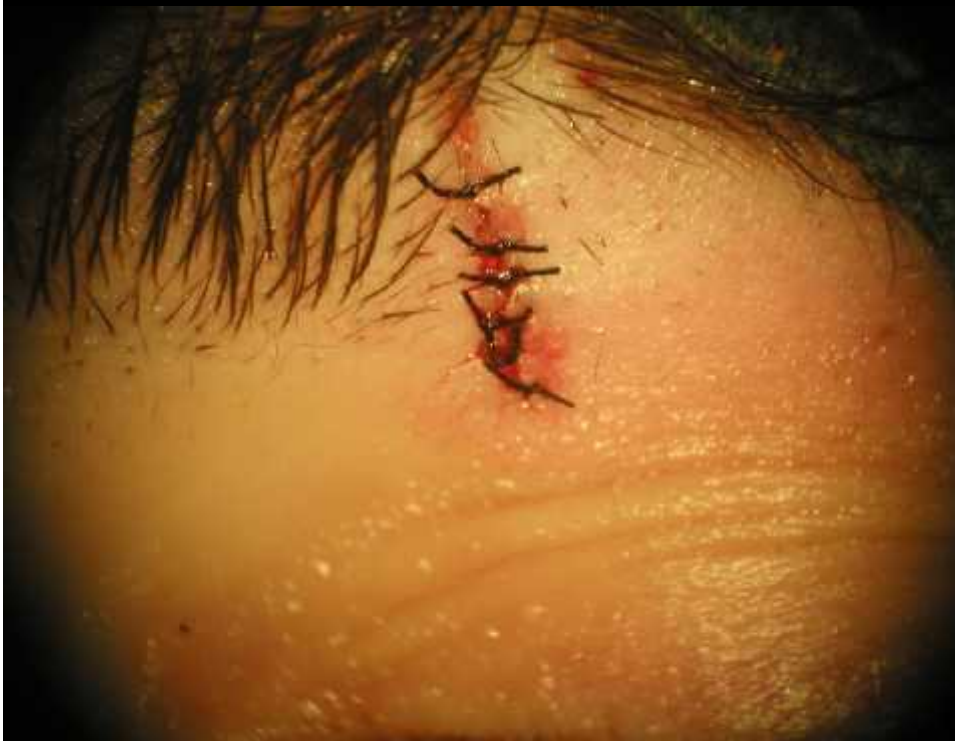:

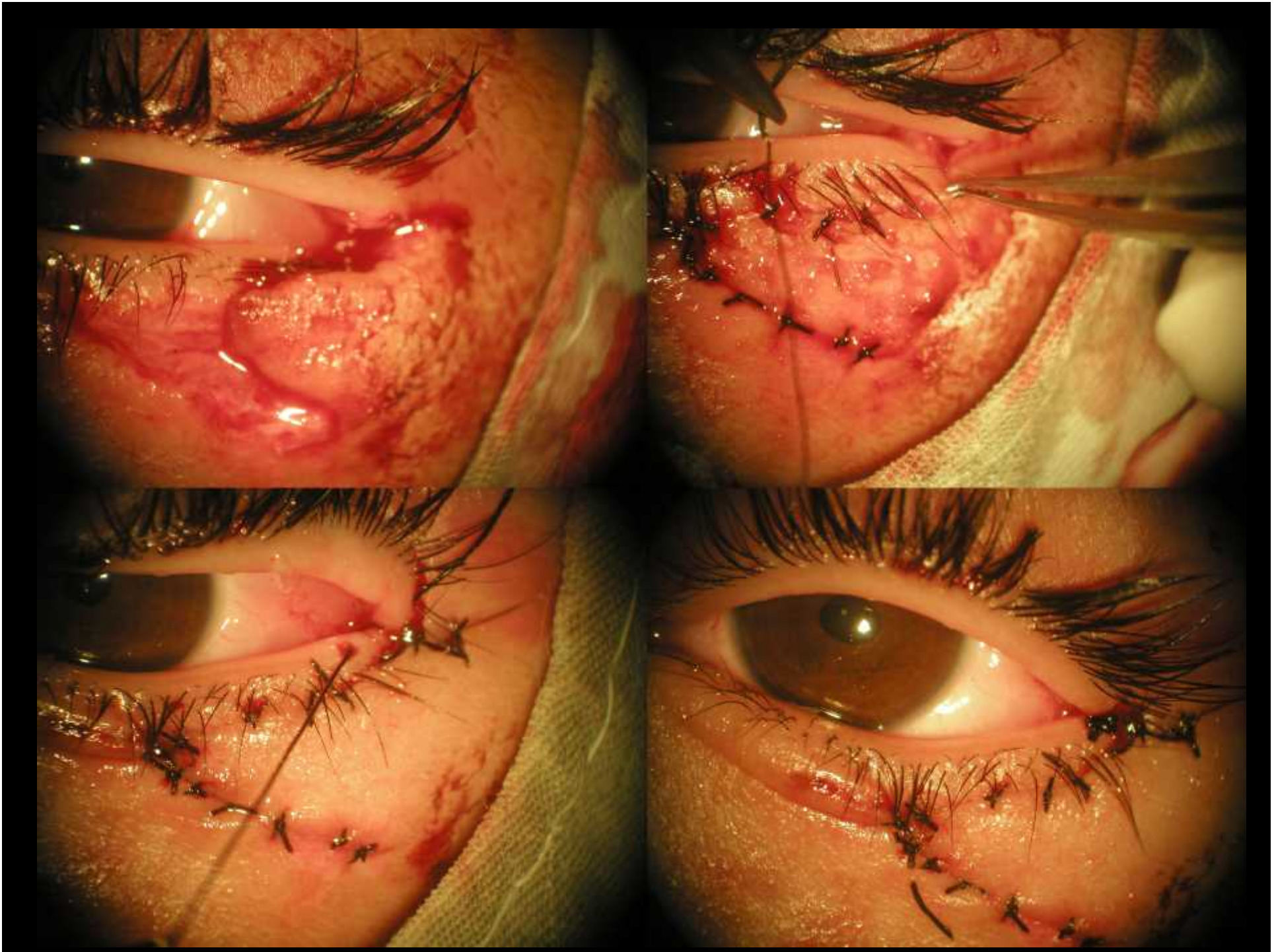
(, R , CAT .)

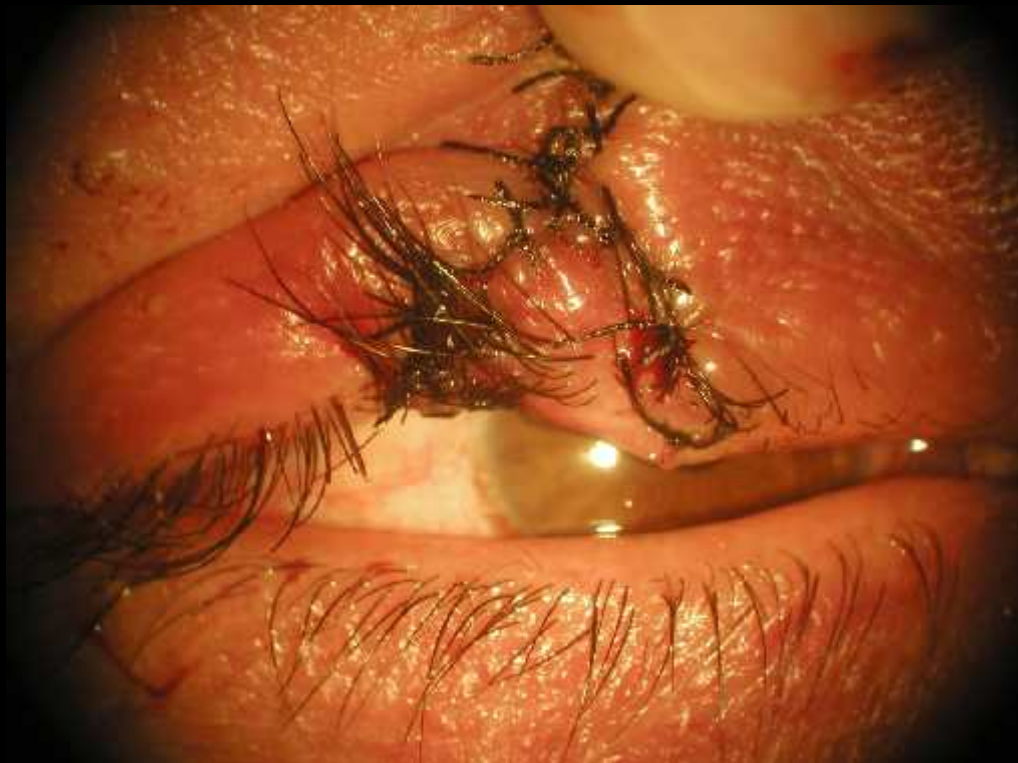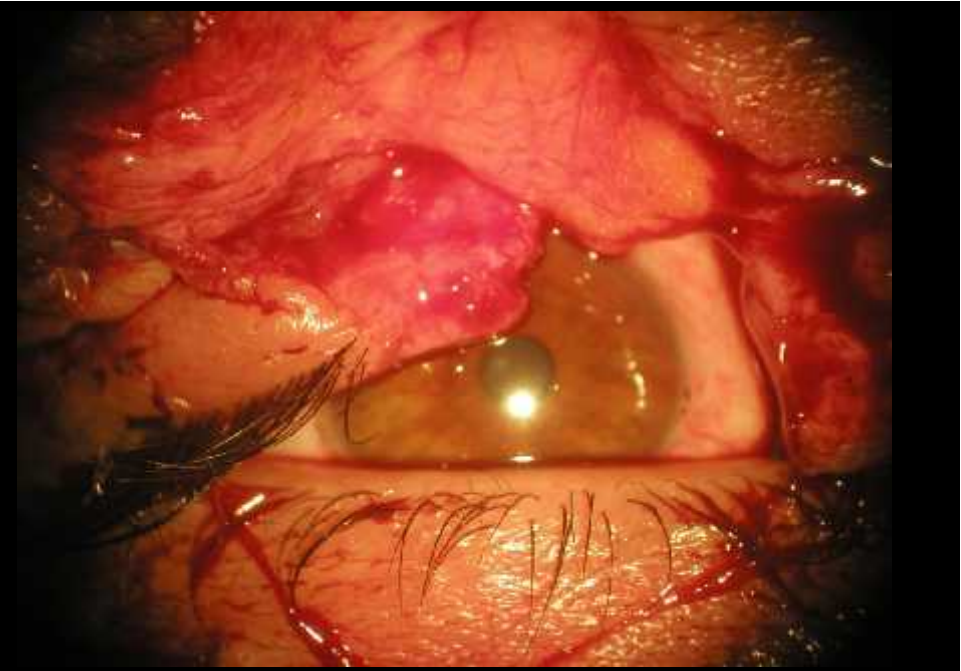
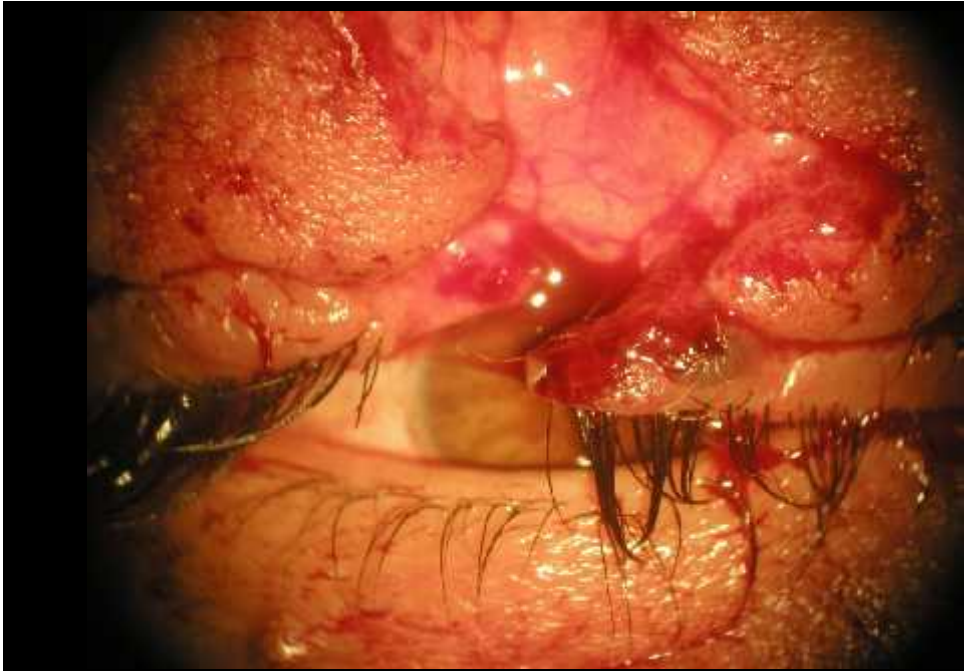
КЛЕТАЧИ

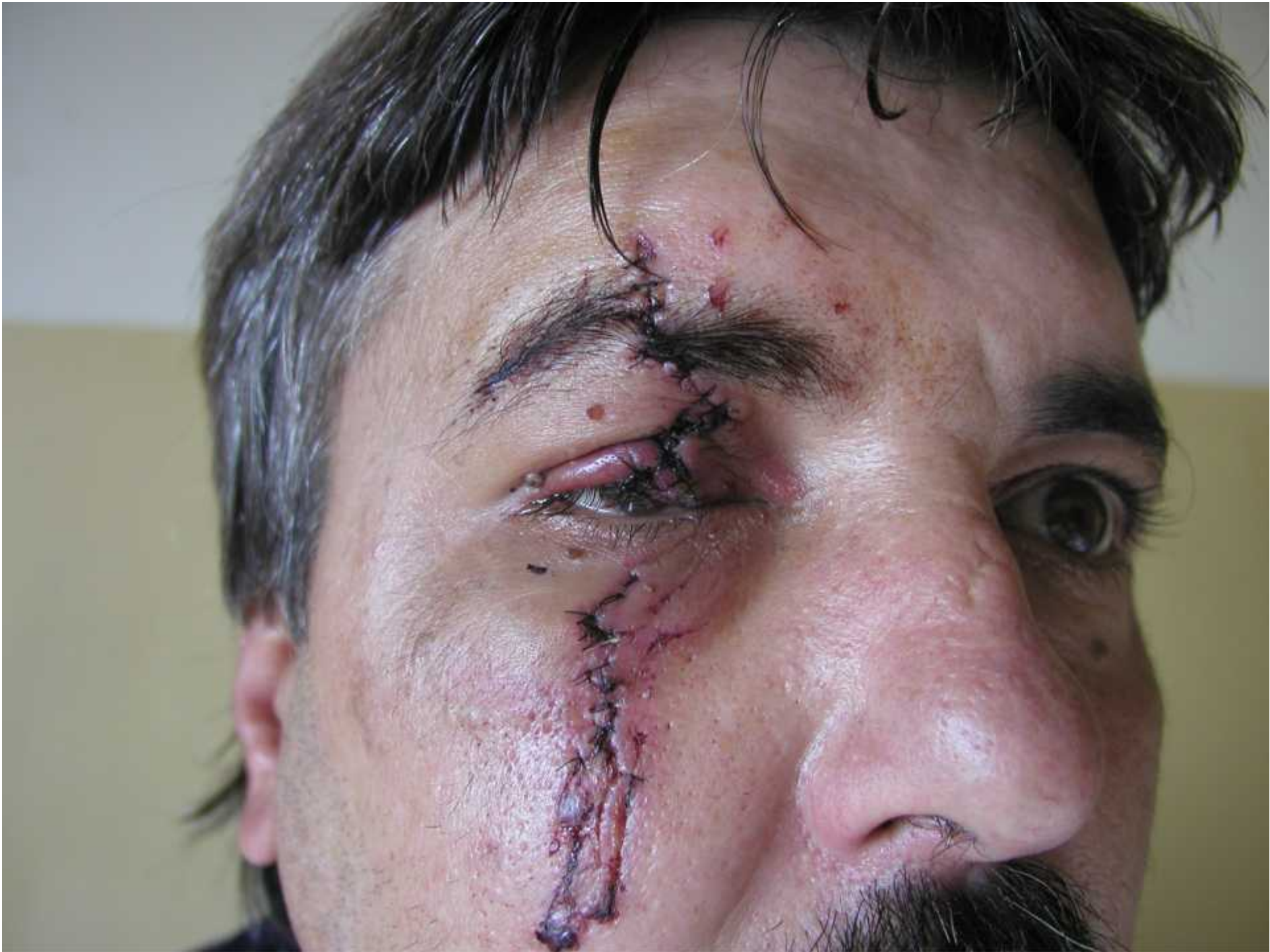

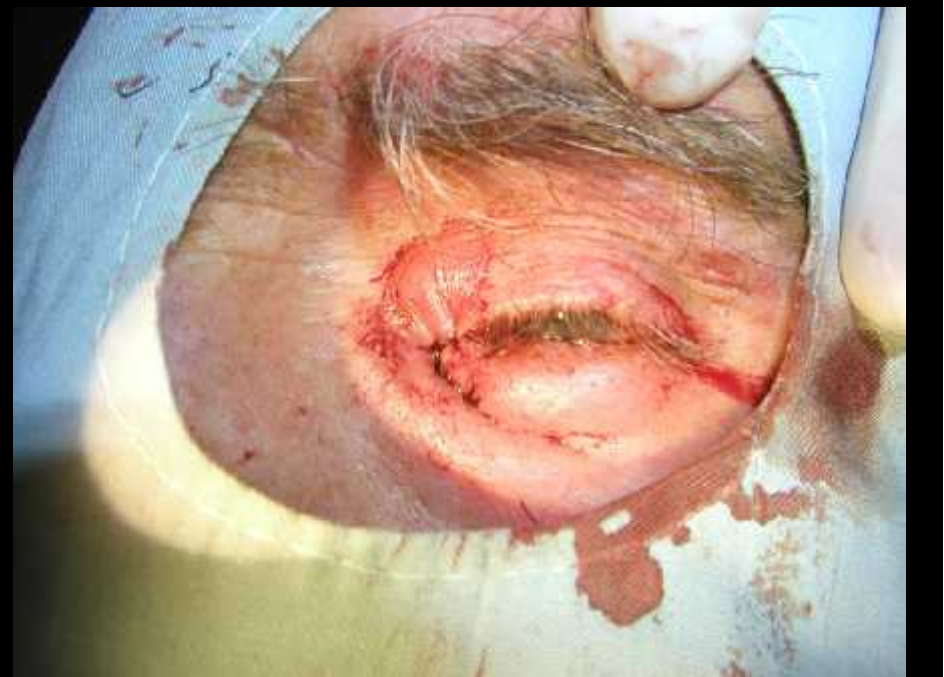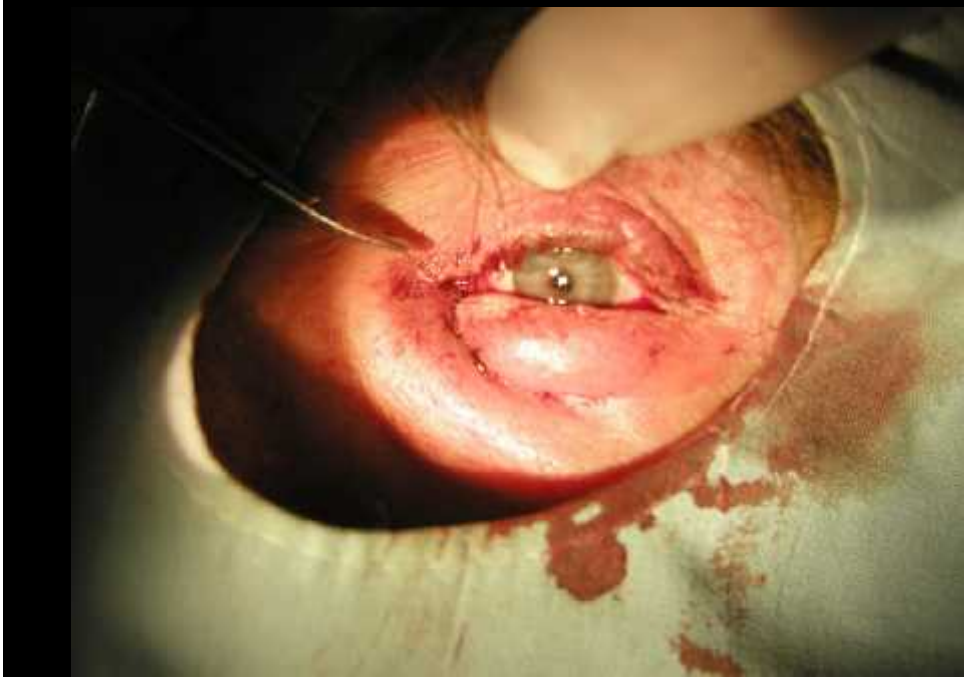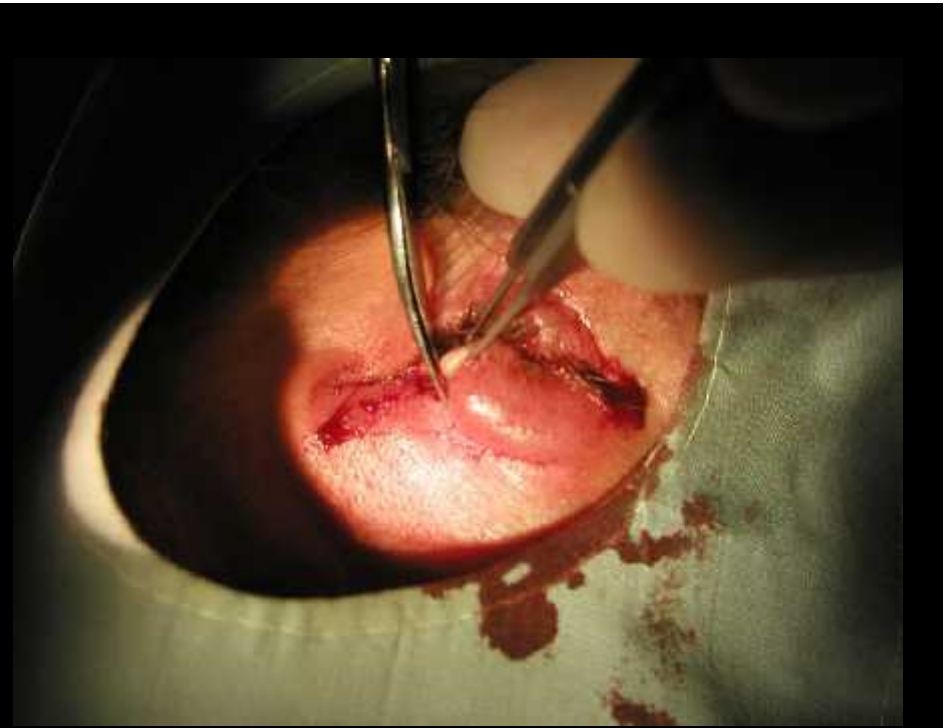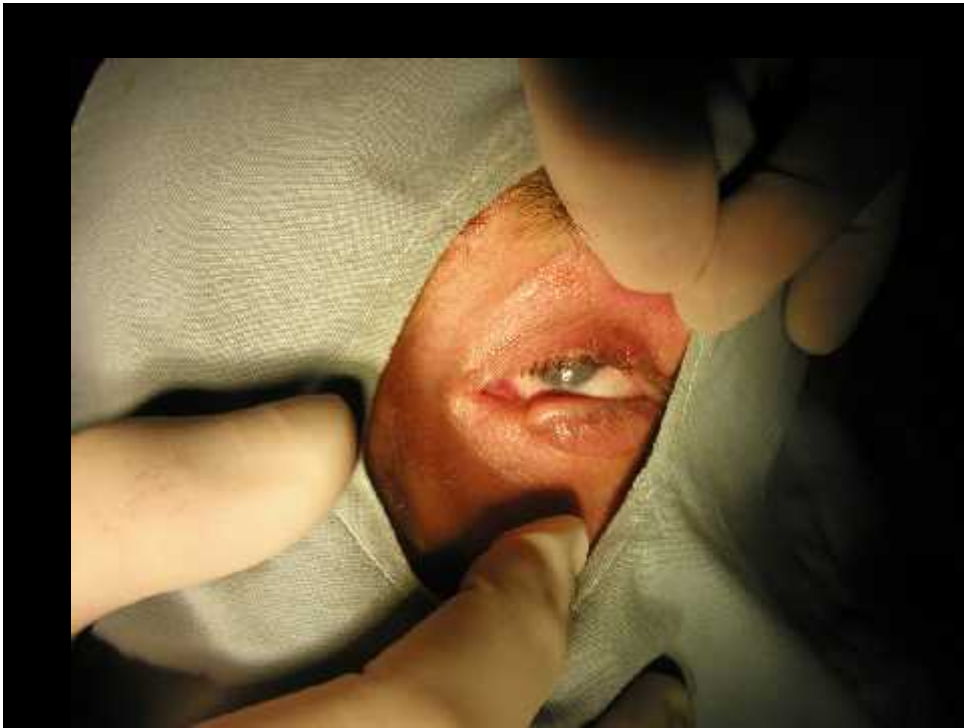КЛЕТАЧНА РАНА - ШЕВ

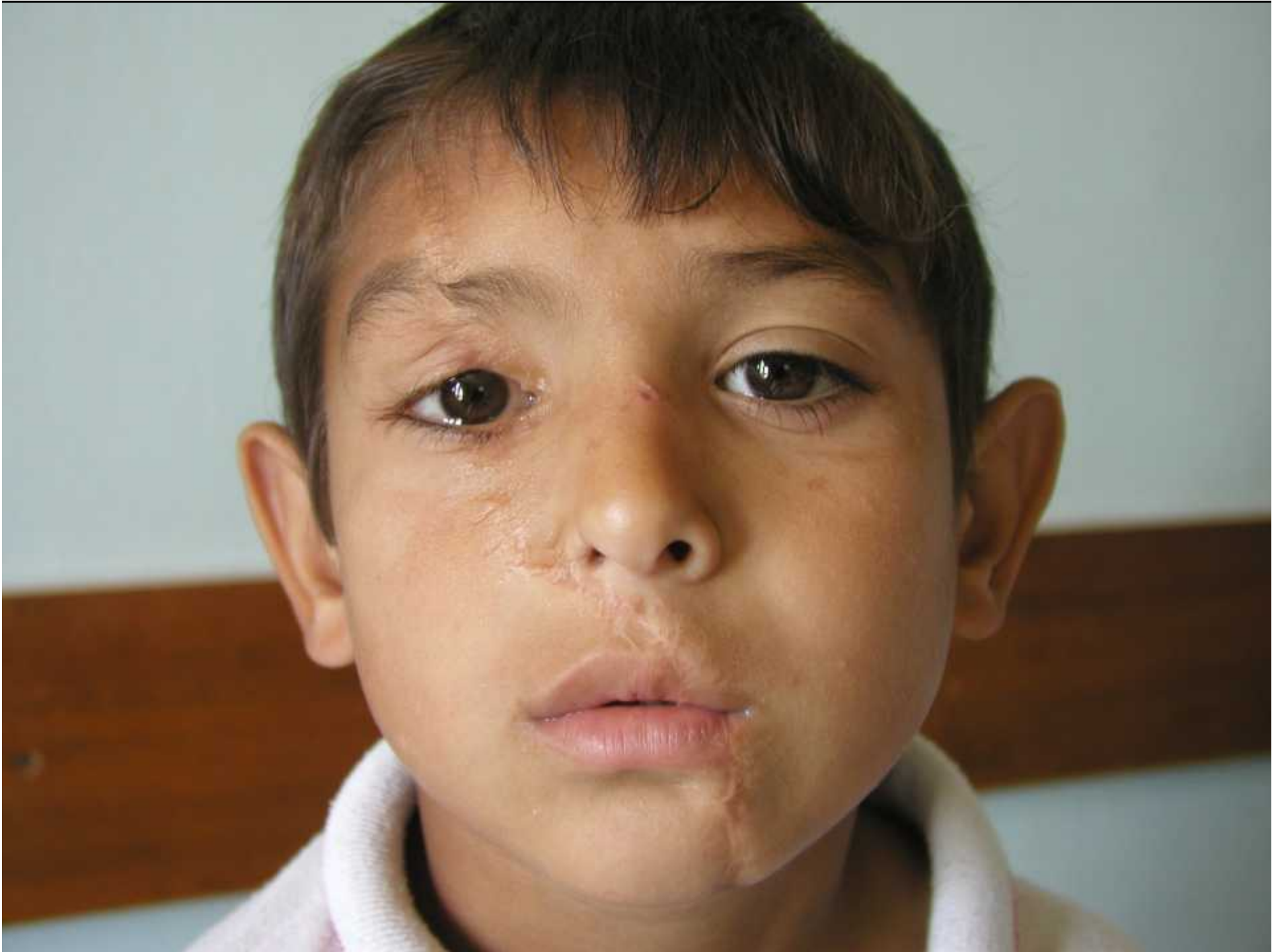


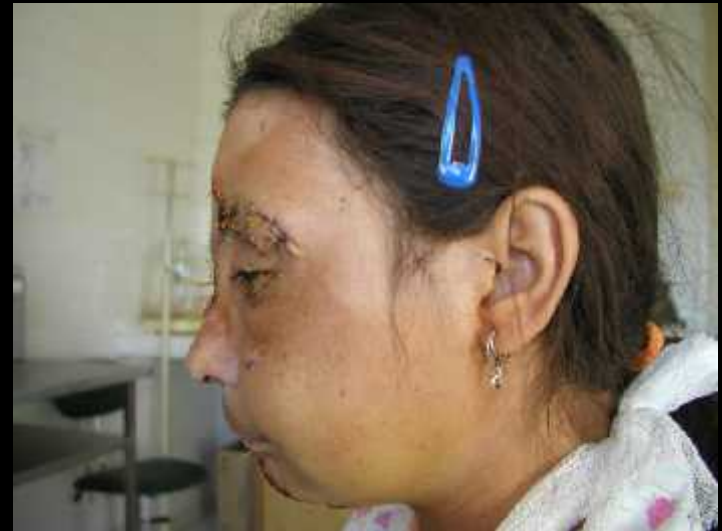
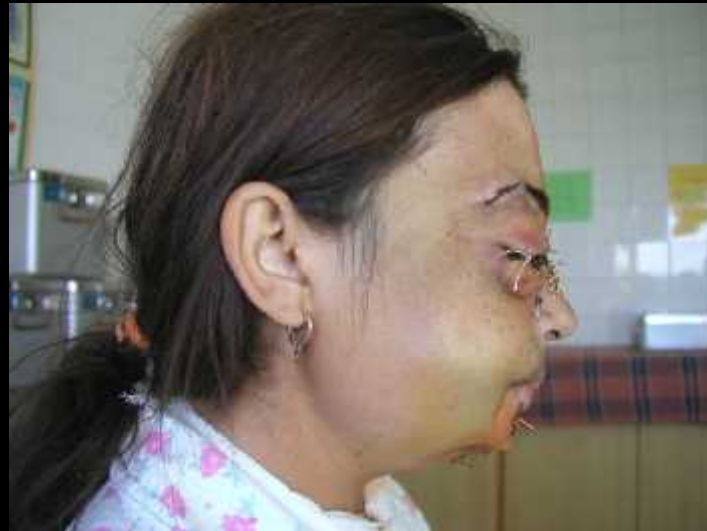
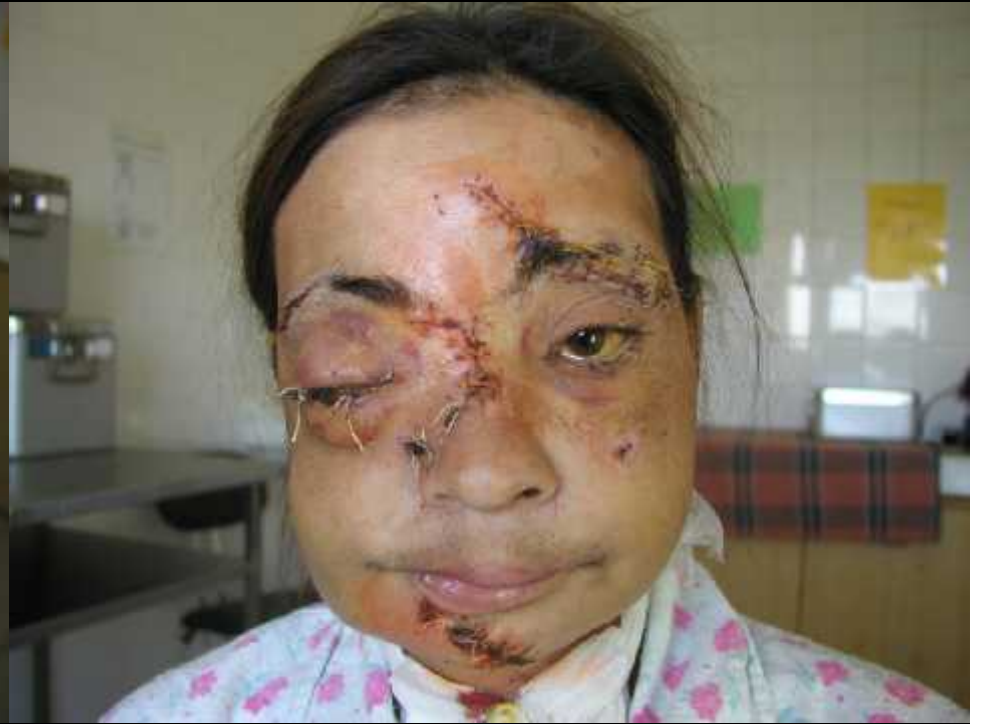
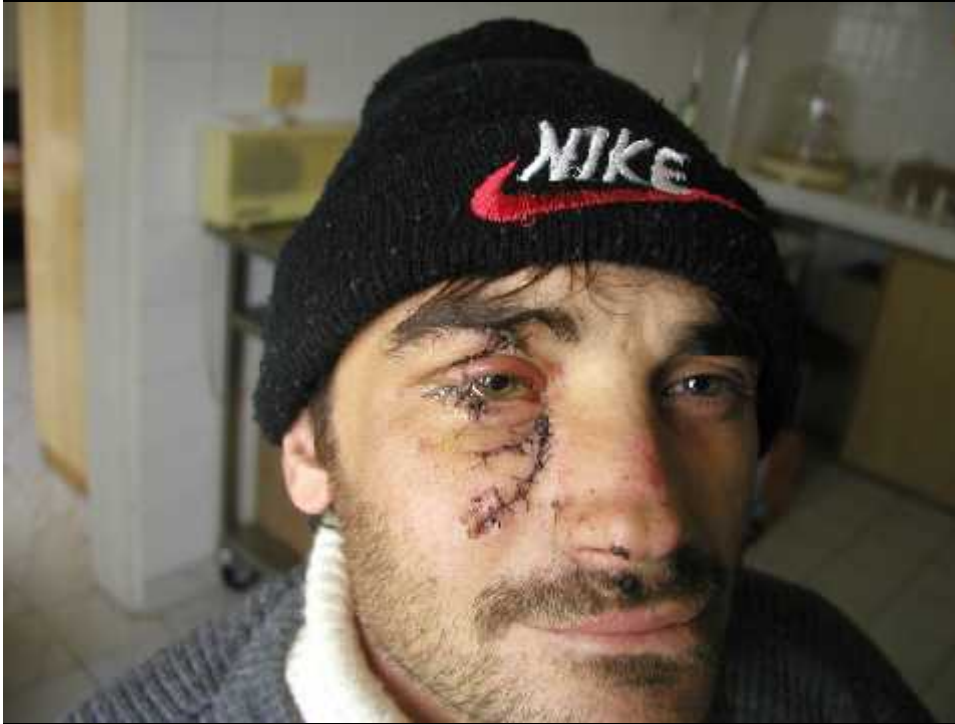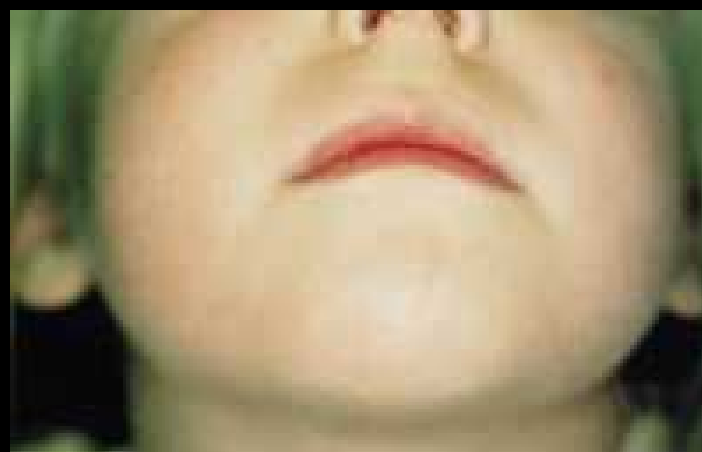




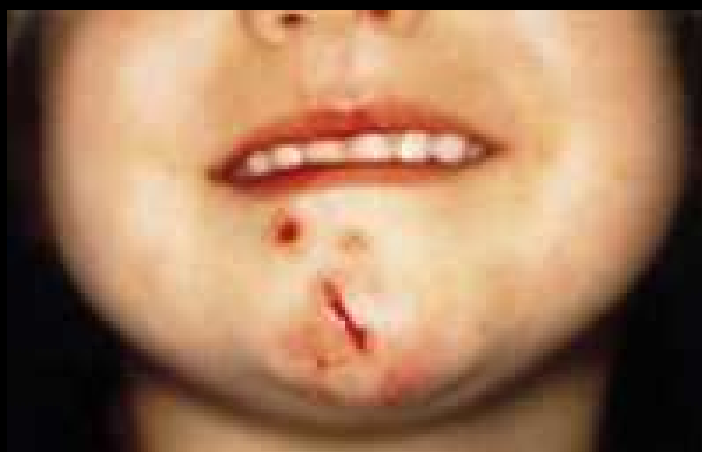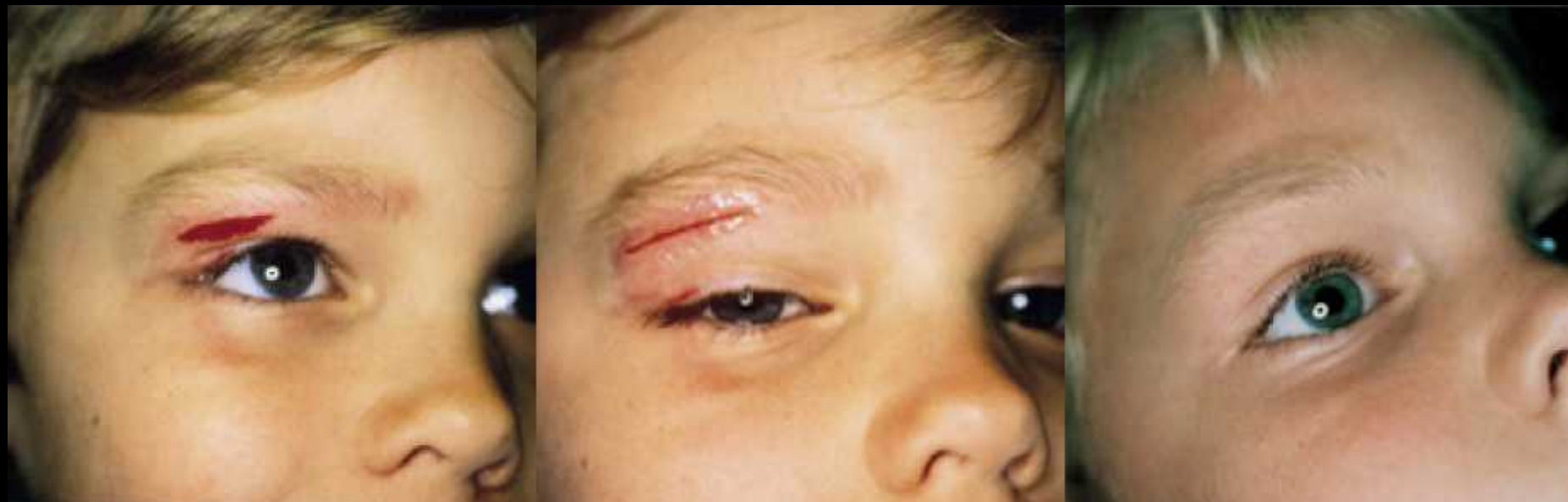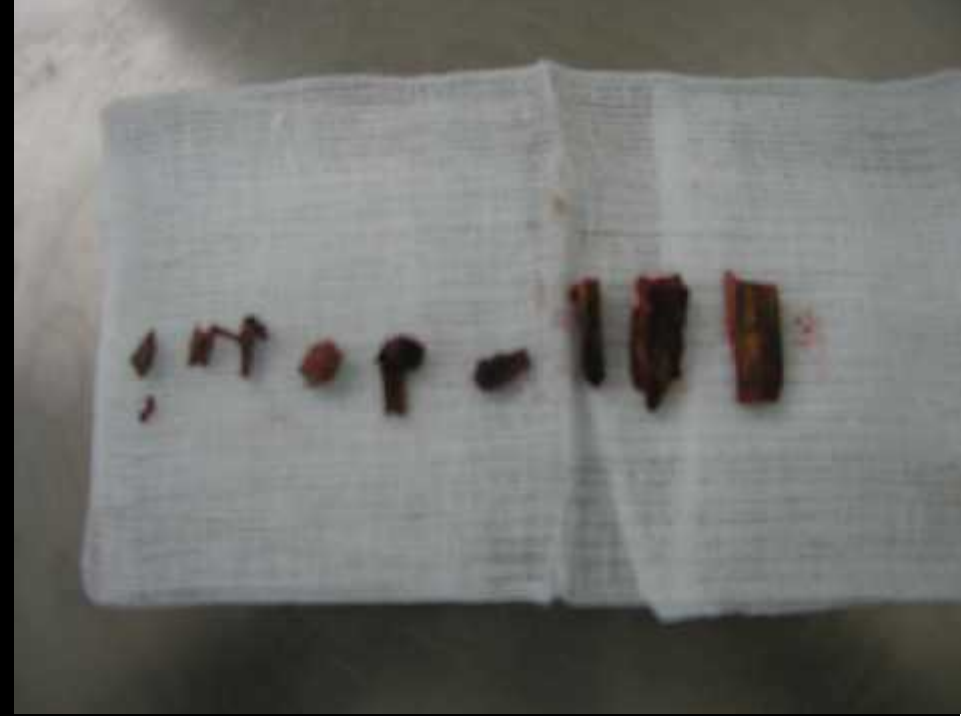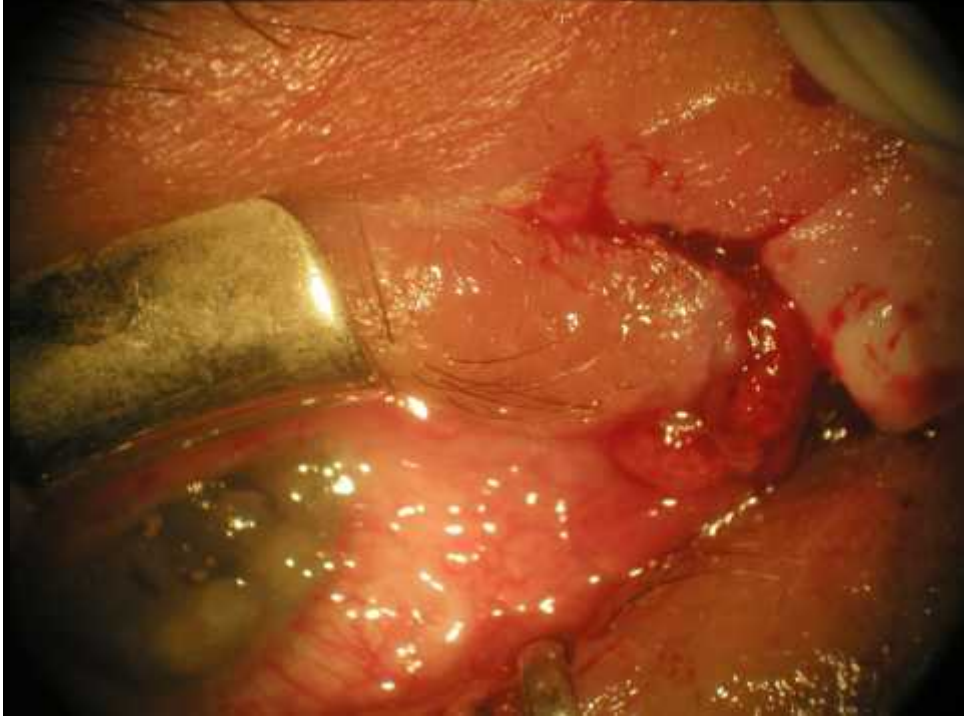




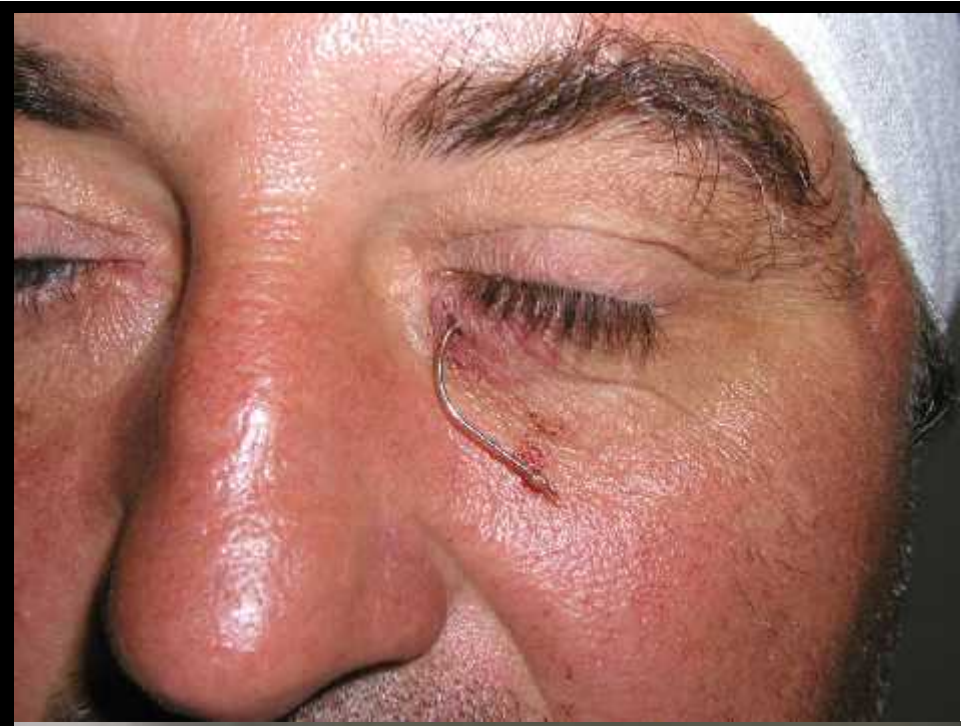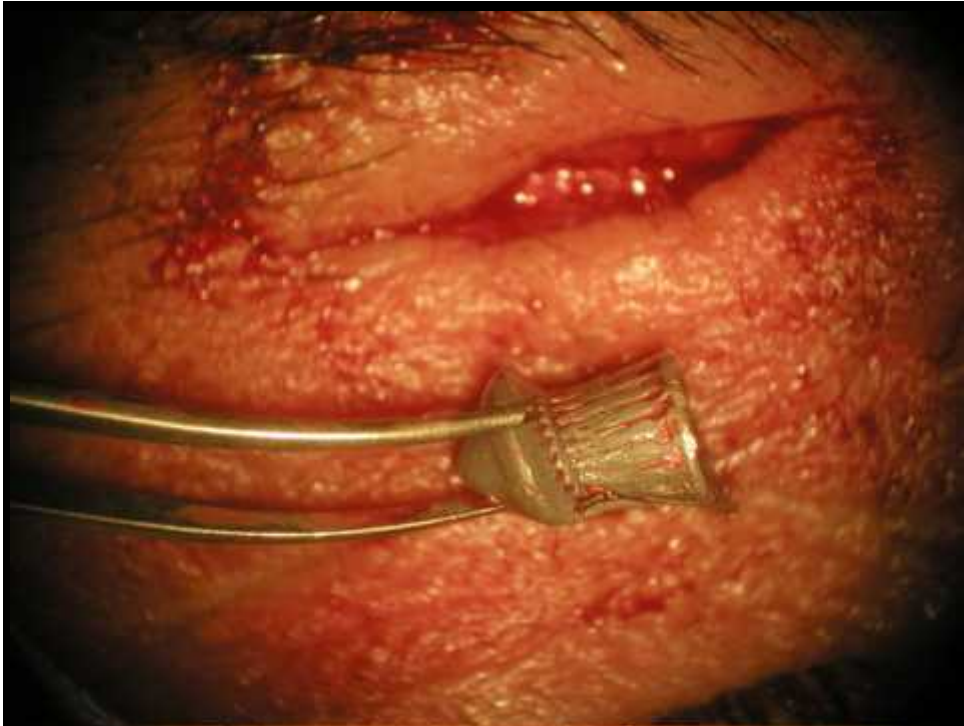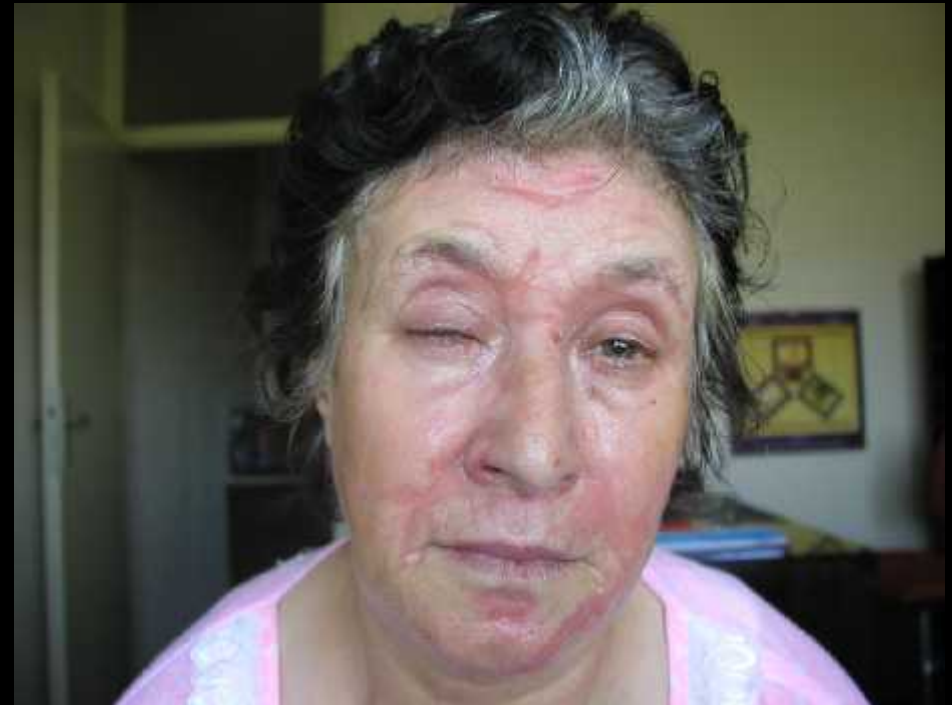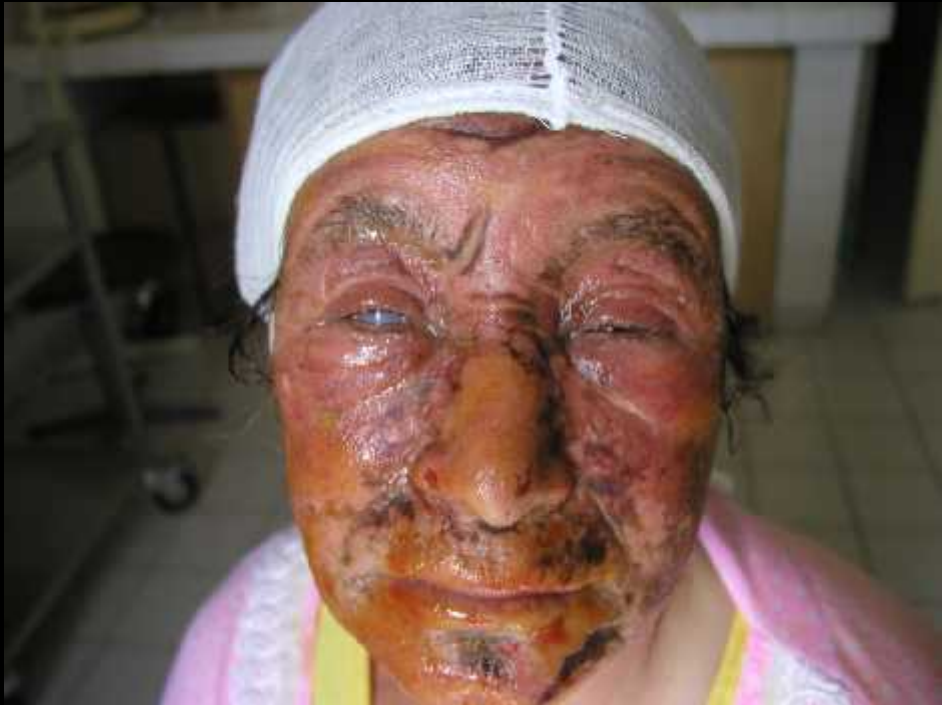КЛЕТАЧНА РАНА ЛЕПИЛНА ТЕХНИКА ЗА АДАПТАЦИЯ



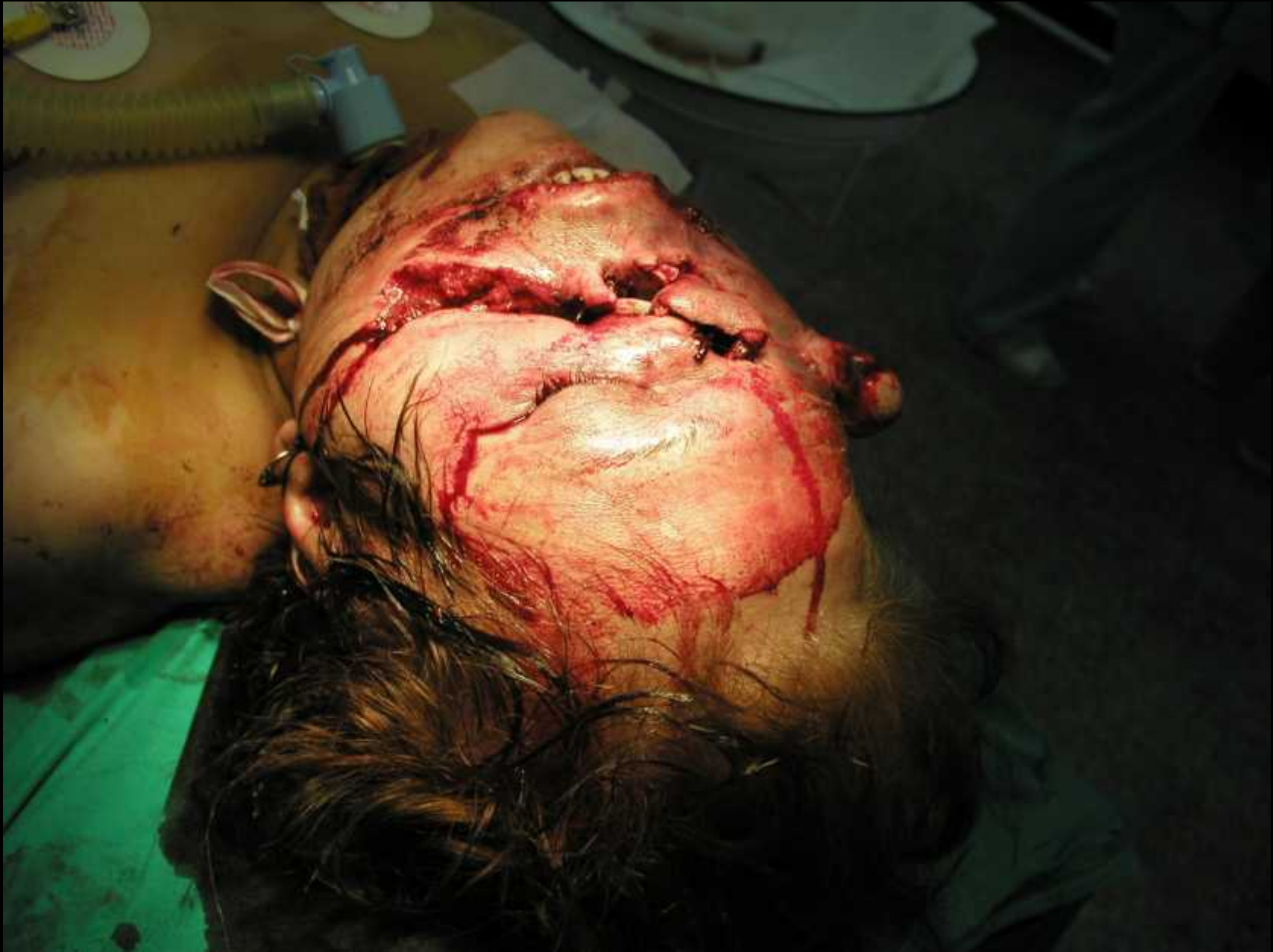КЛЕТЧАЧНА РАНА С ЧУЖДИ ТЕЛА



COMBUSTIO



CONQUASATIO



ПЪРВА ПОМОЩ

■
■

-

-

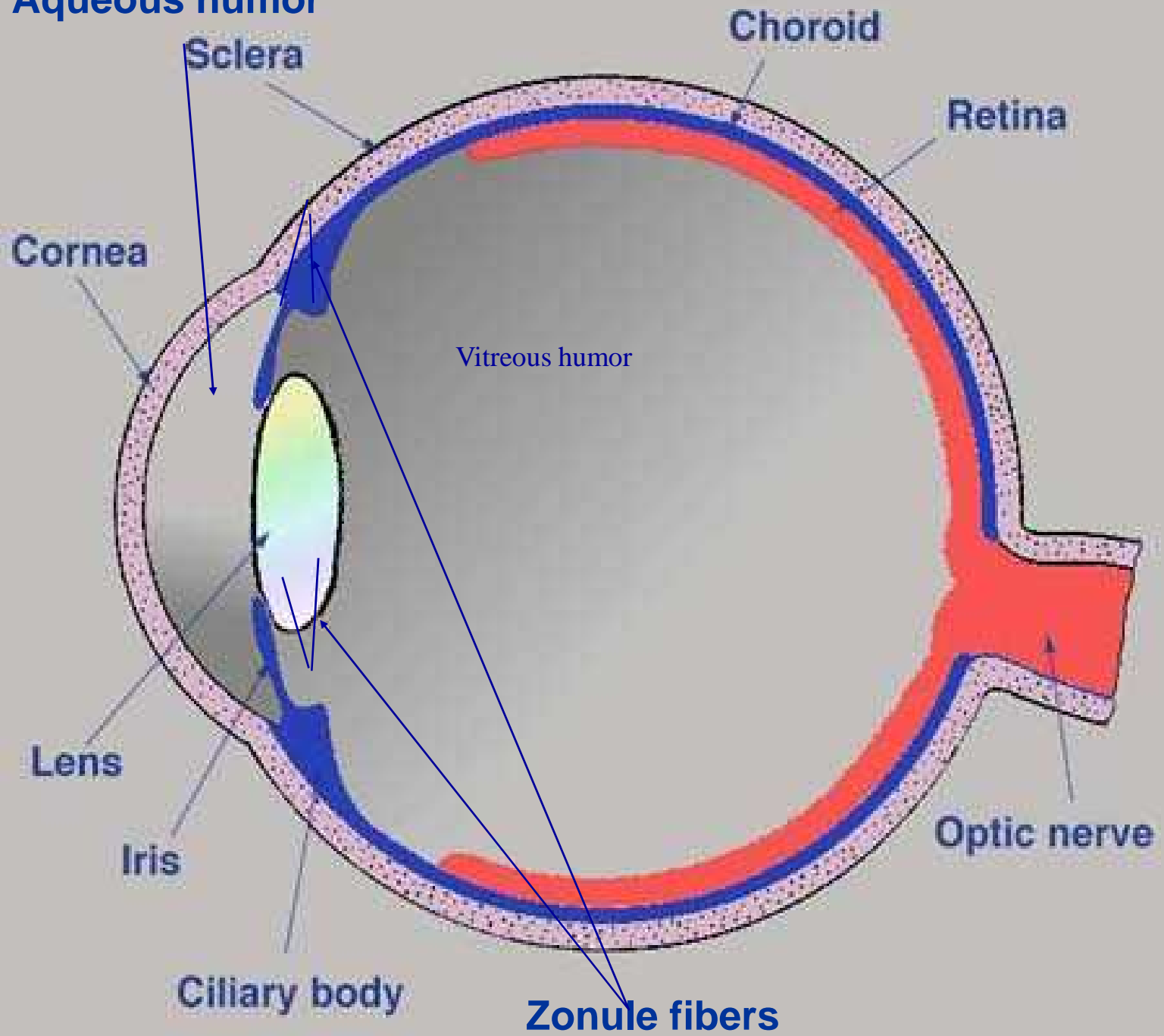
-

-

-

ТРАВМИ НА ОКОТО

Aqueous humor



Choroid

Retina

Cornea

Vitreous humor

Lens

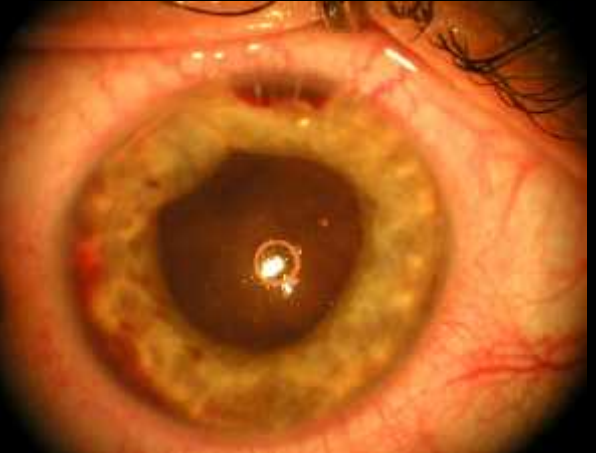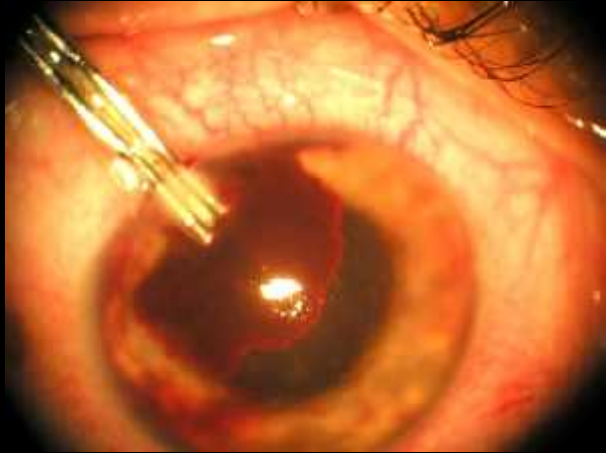
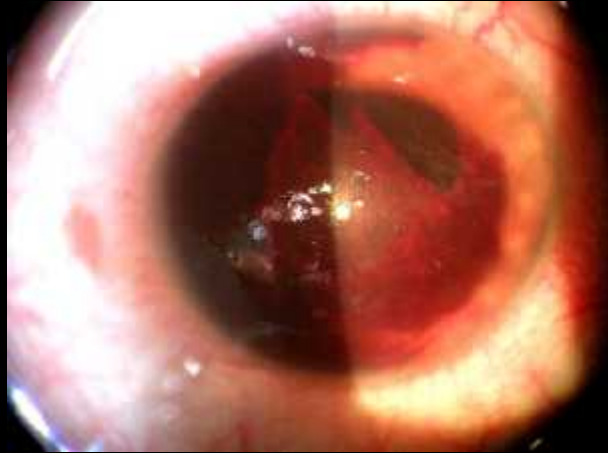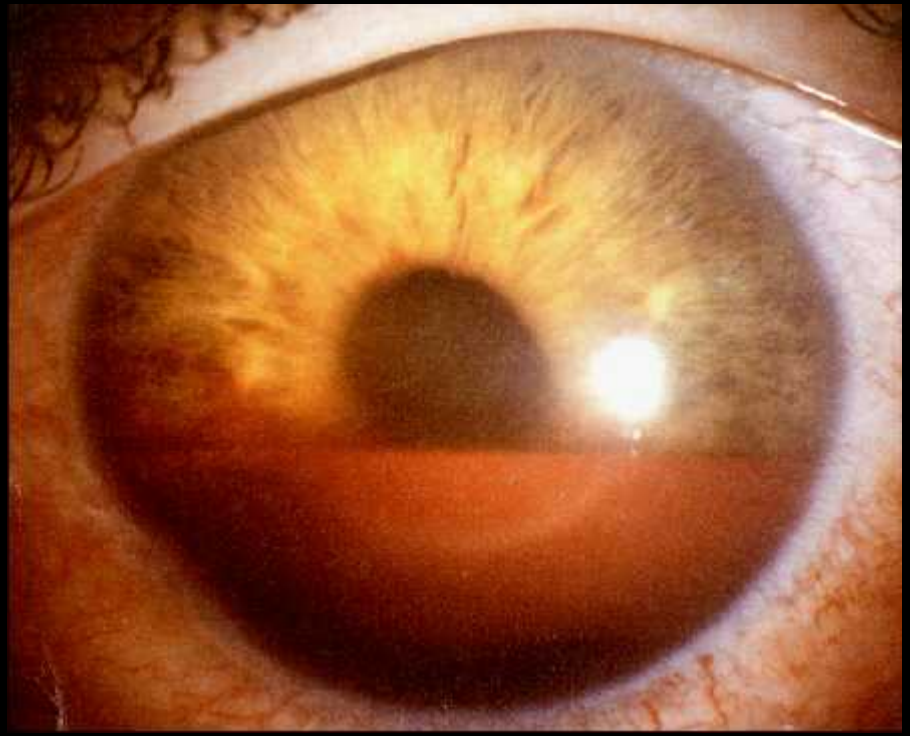
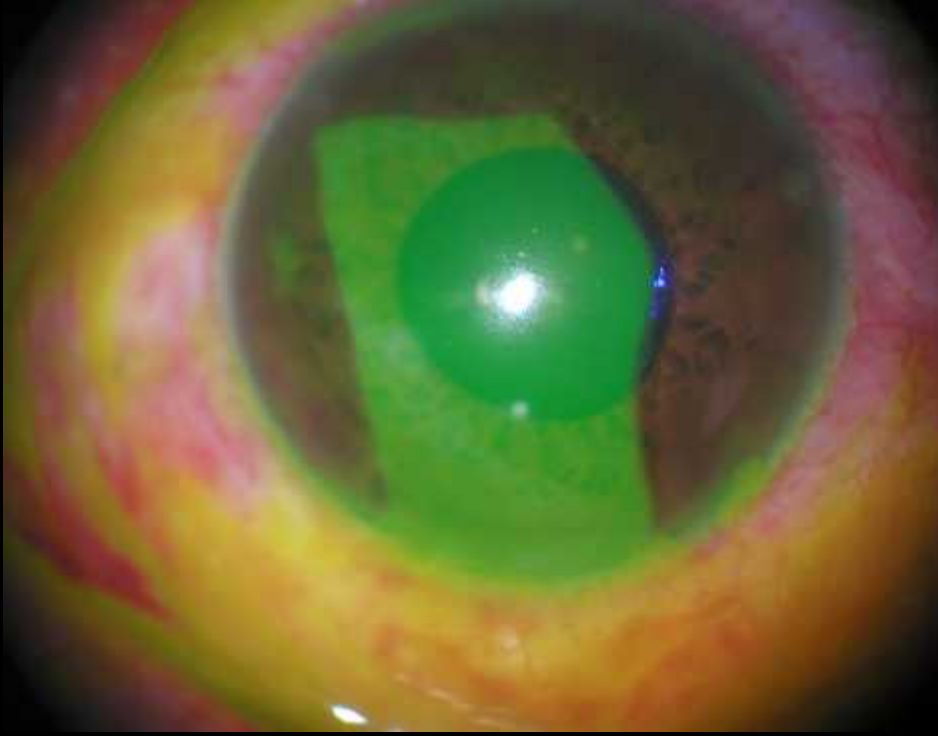Iris

Ciliary body

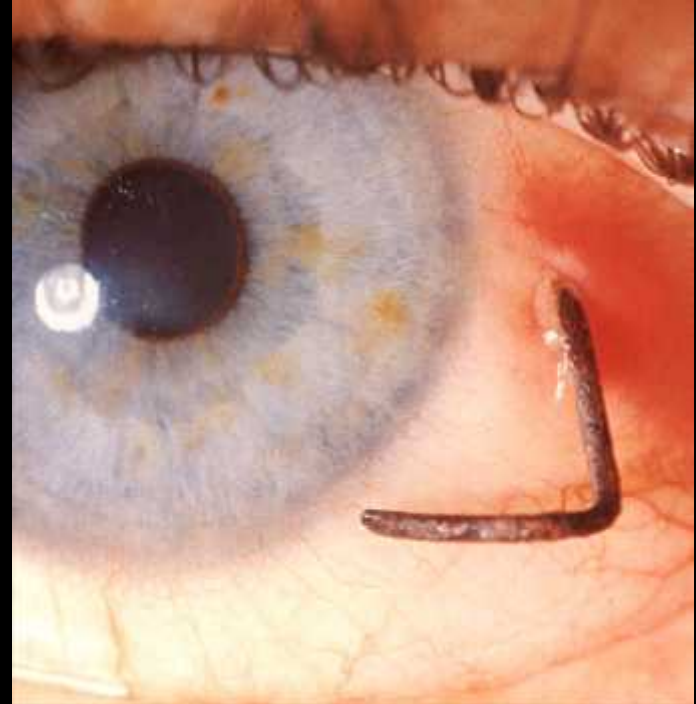
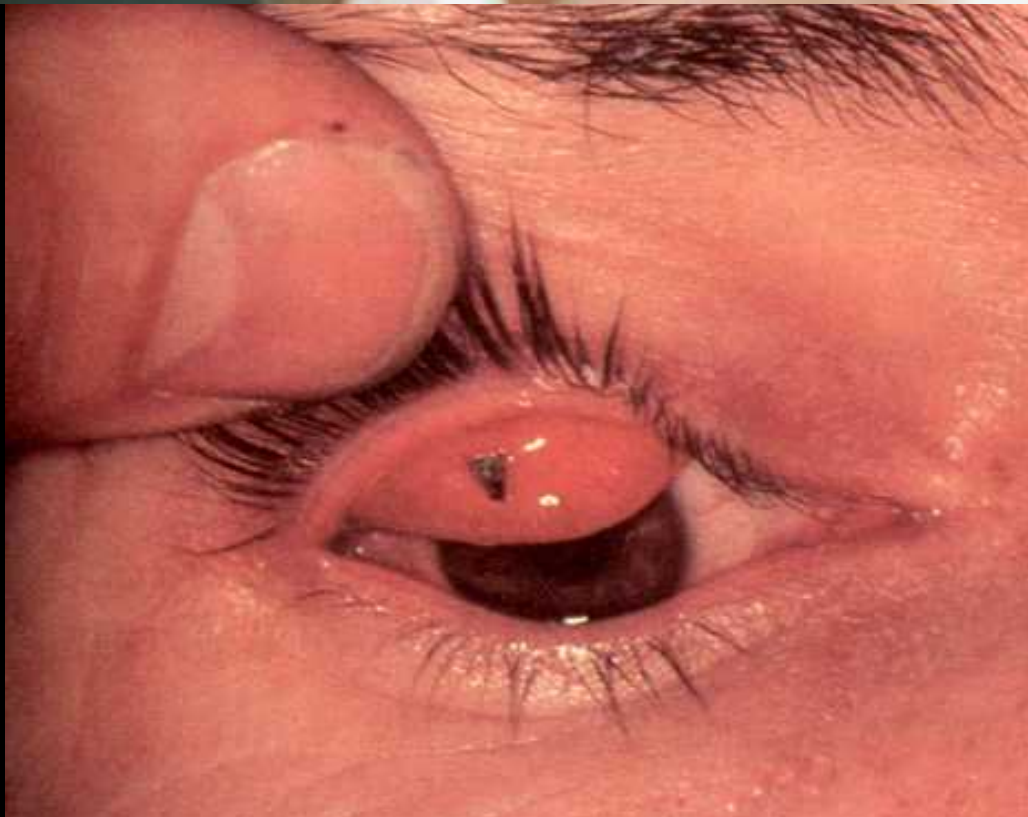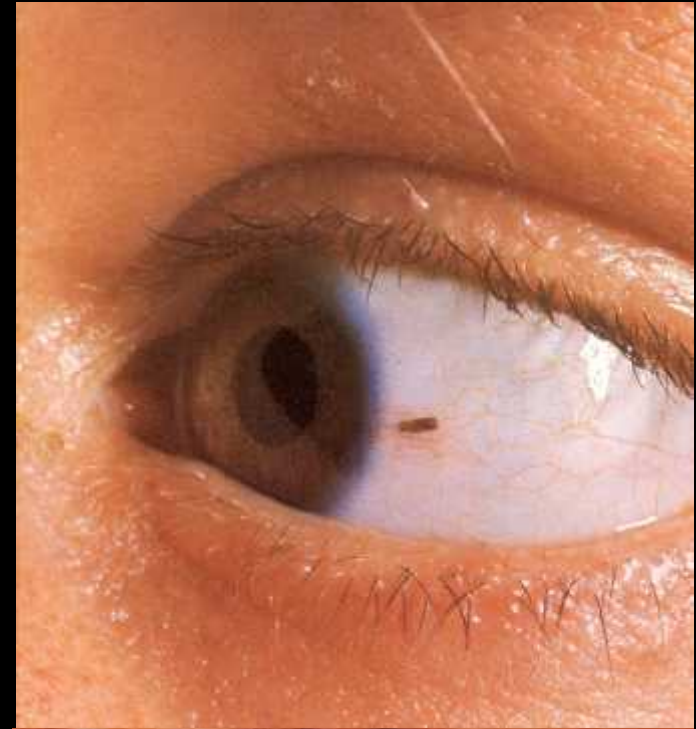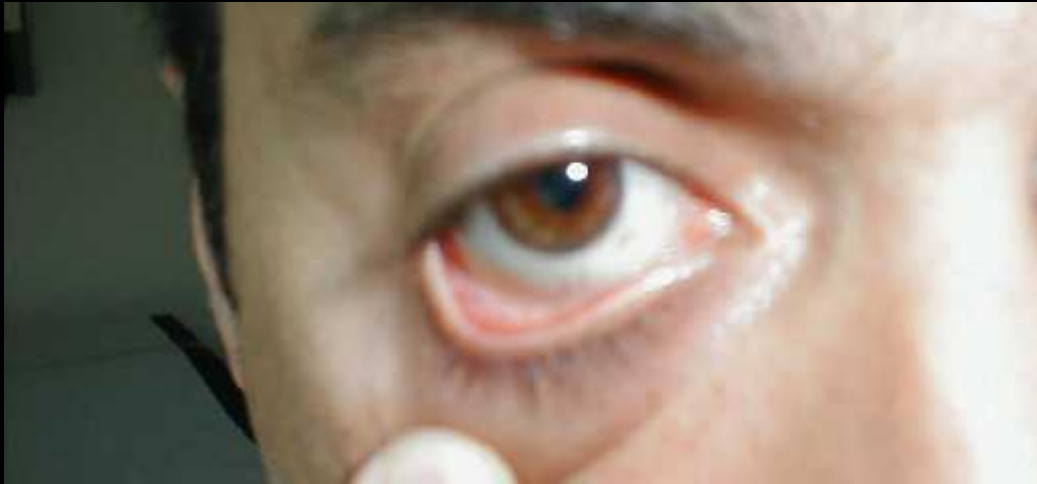Zonule fibers

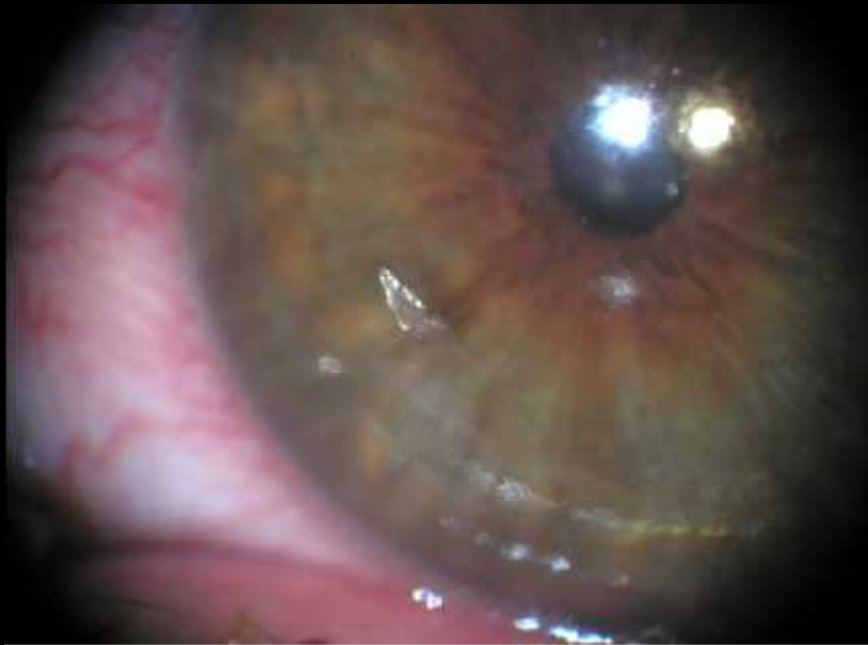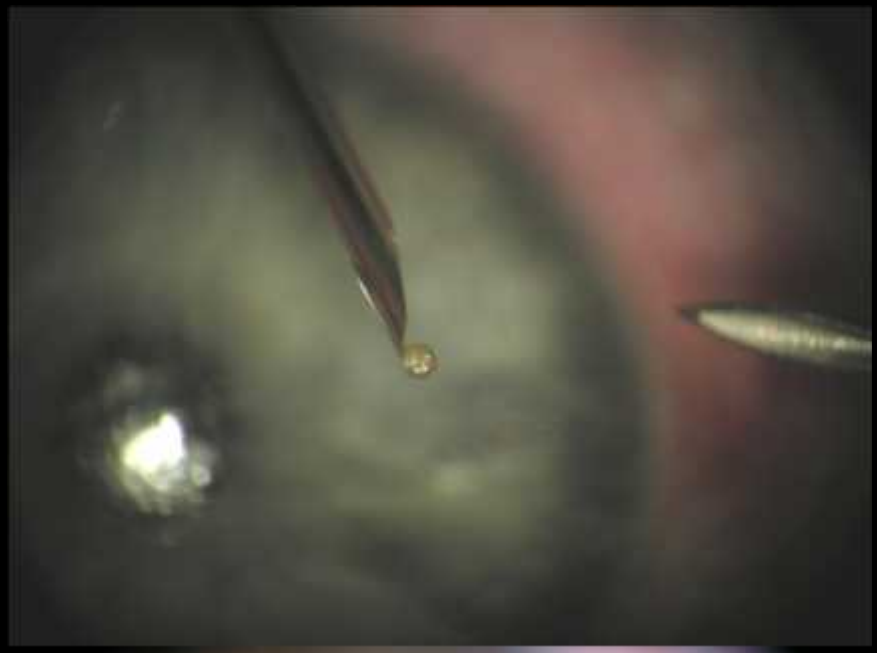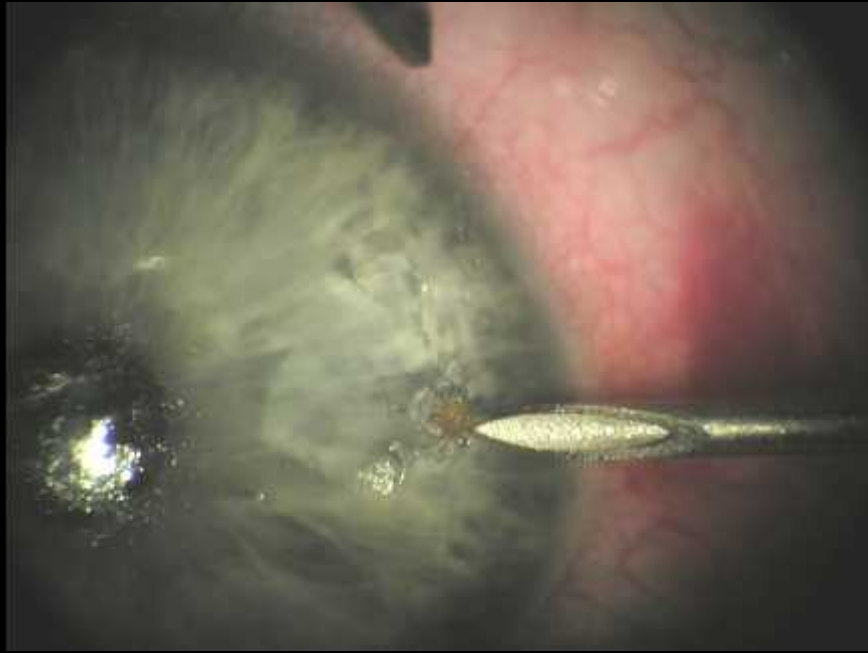Optic nerve

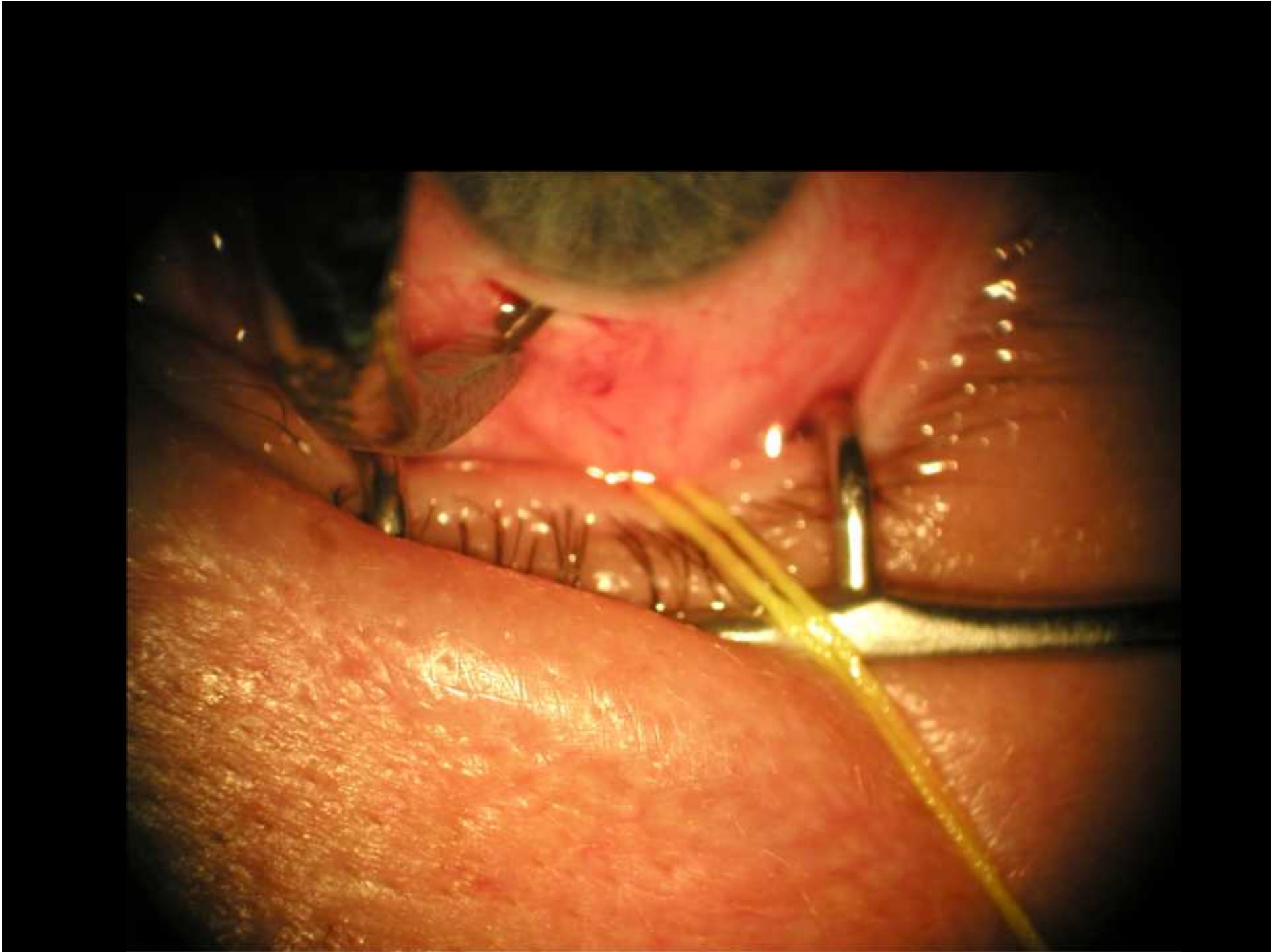КОНТУЗИИ НА ОКОТО

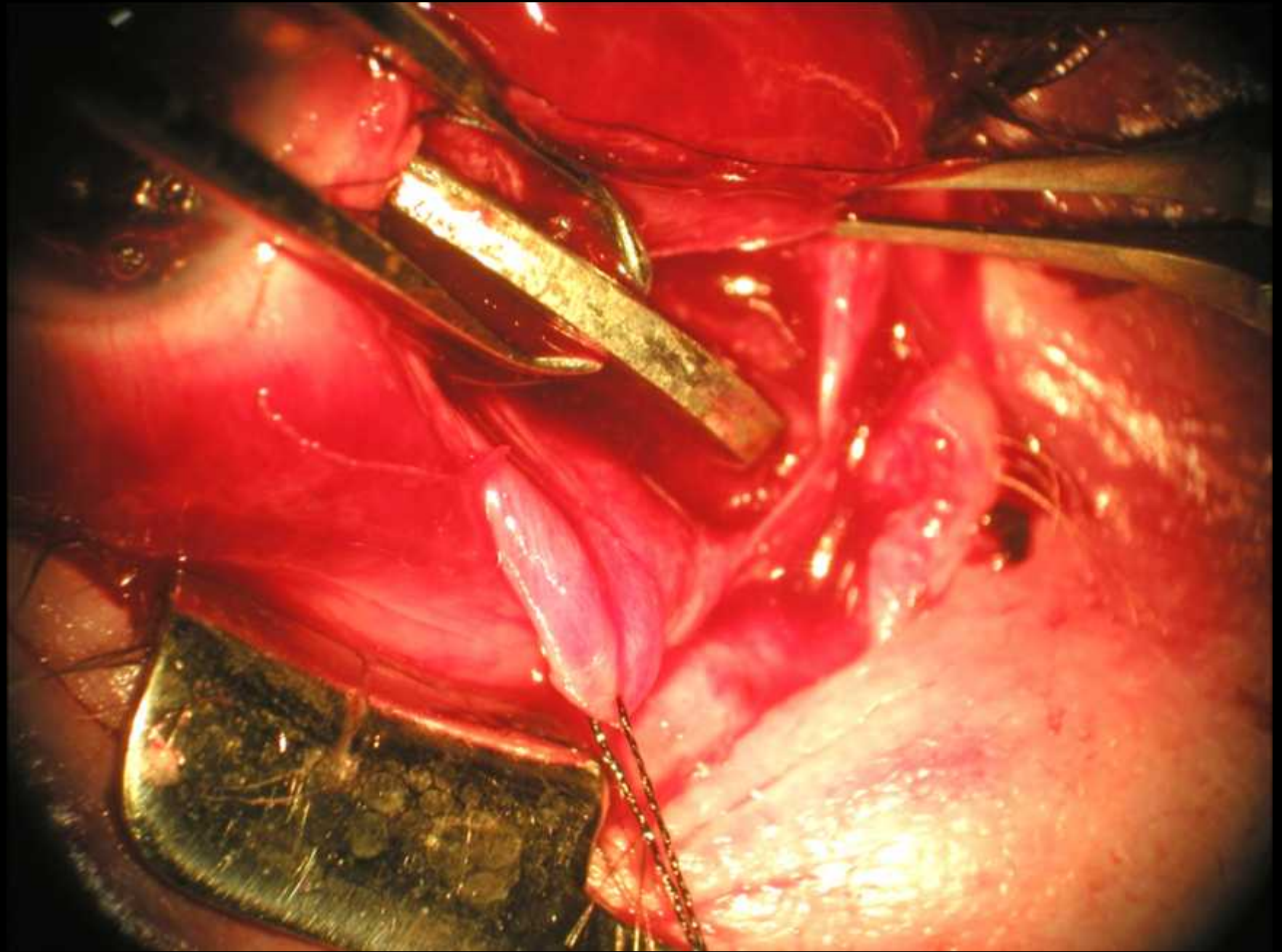


НАРАНЯВАНИЯ НА
ОКОТО С ЧУЖДО
ТЯЛО

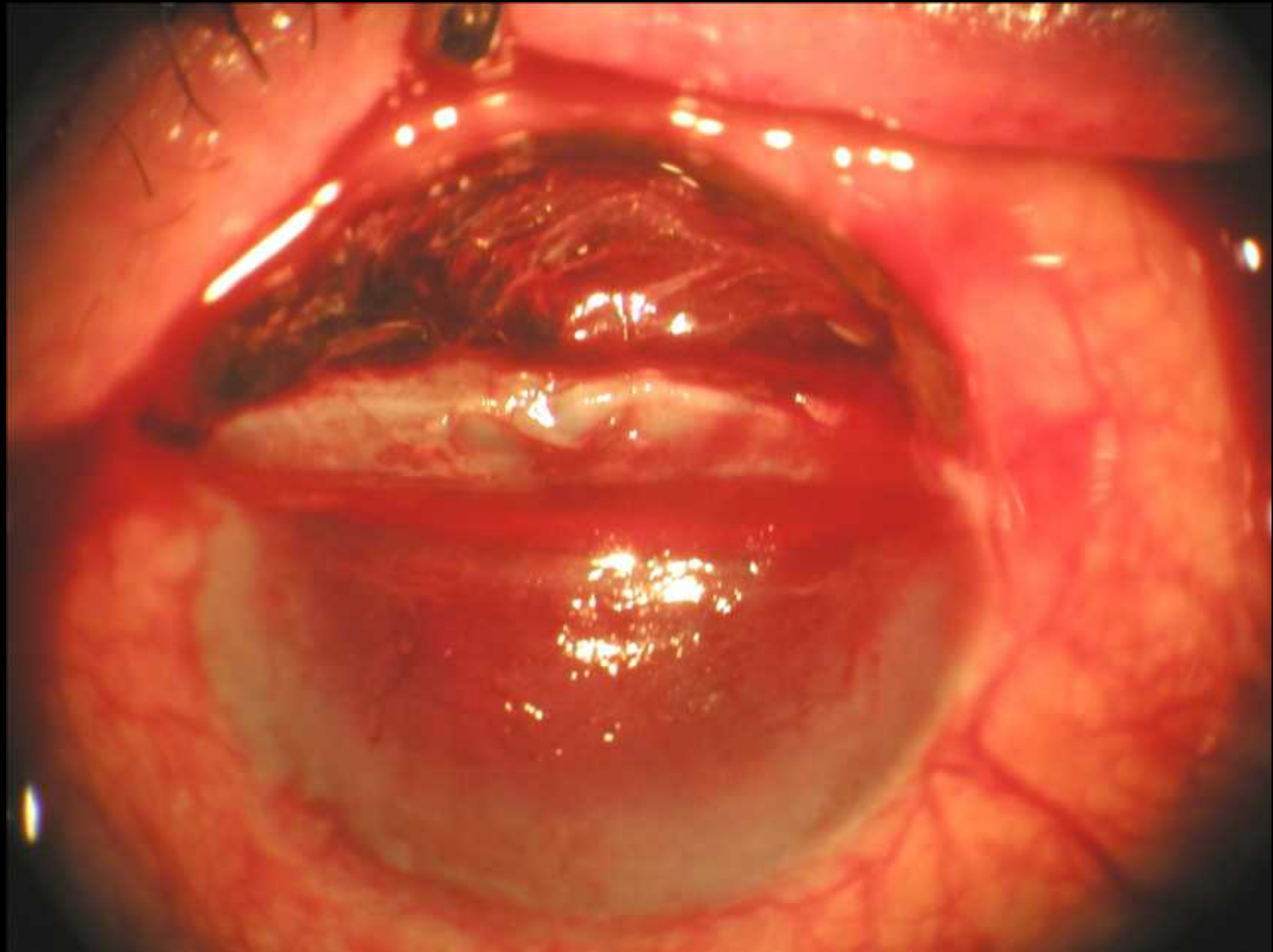


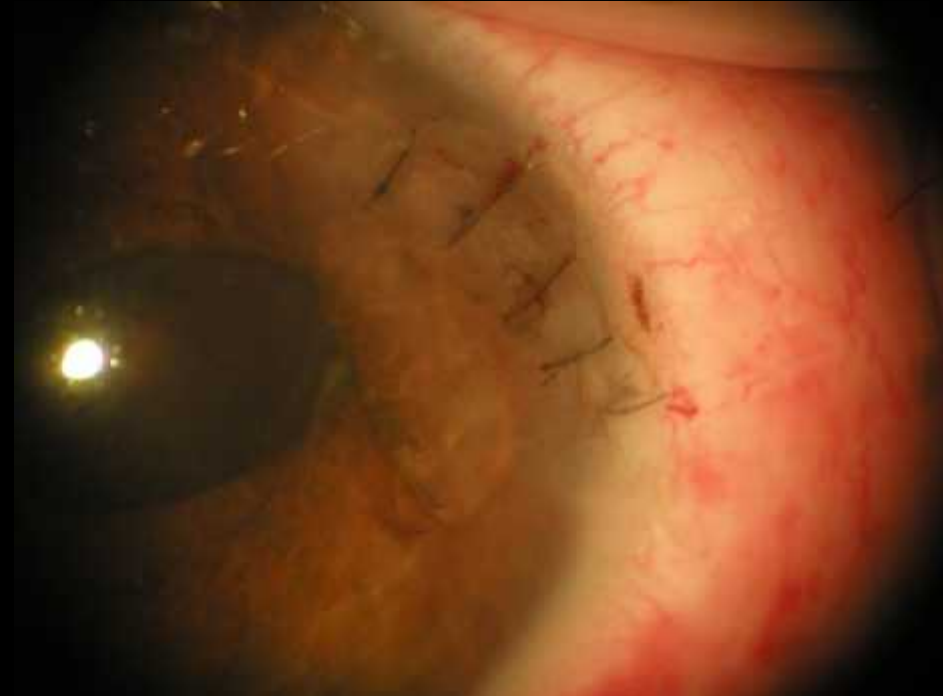
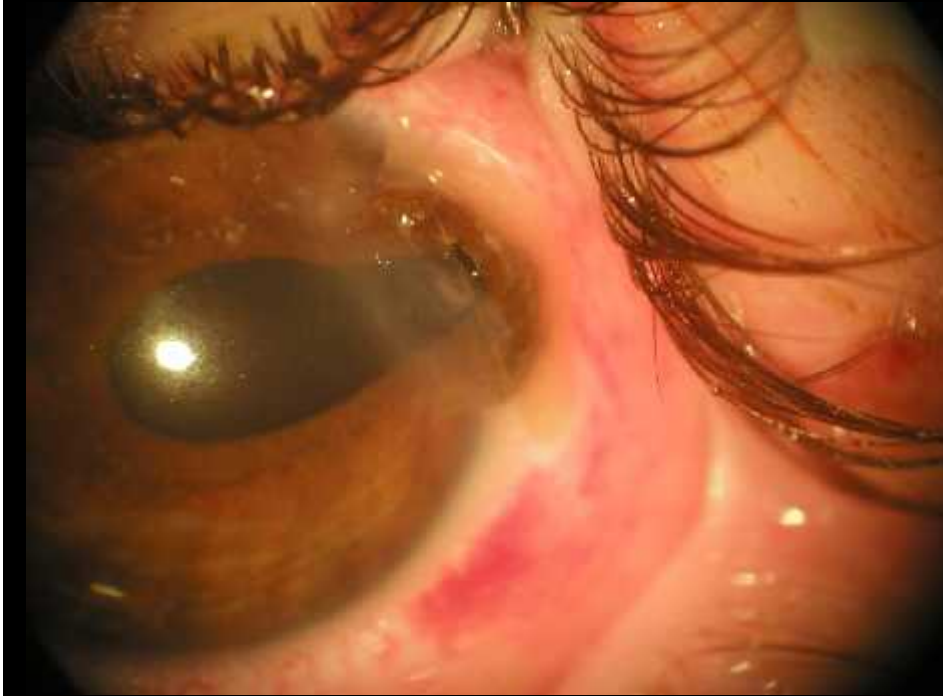


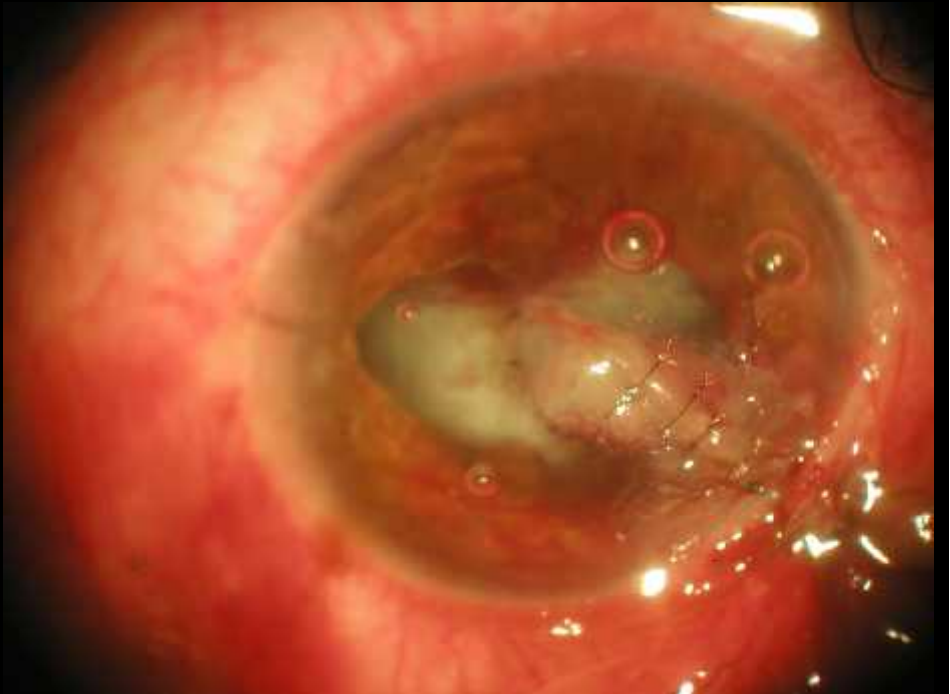
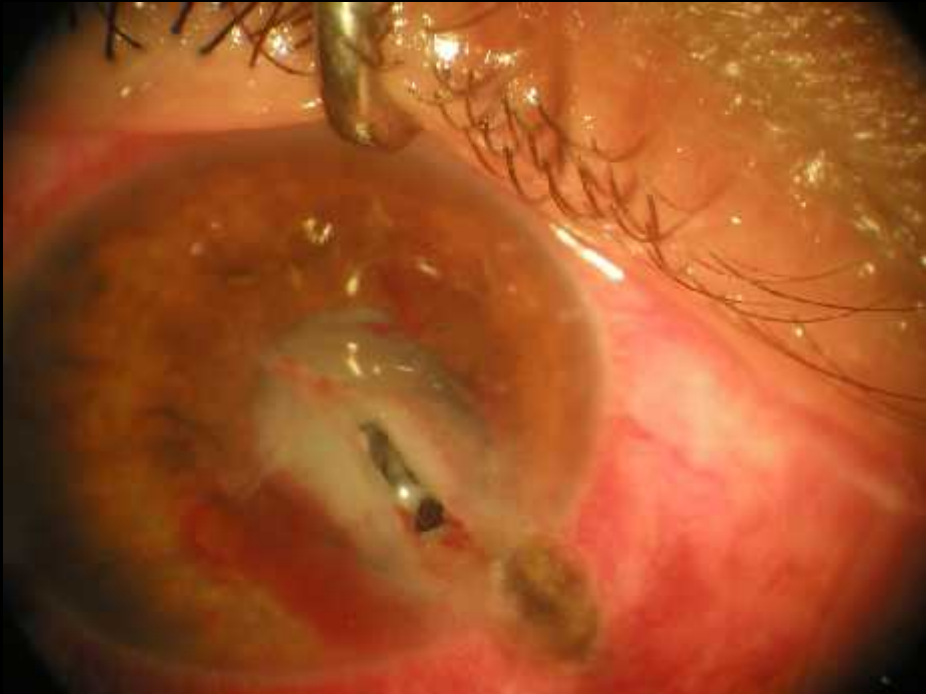


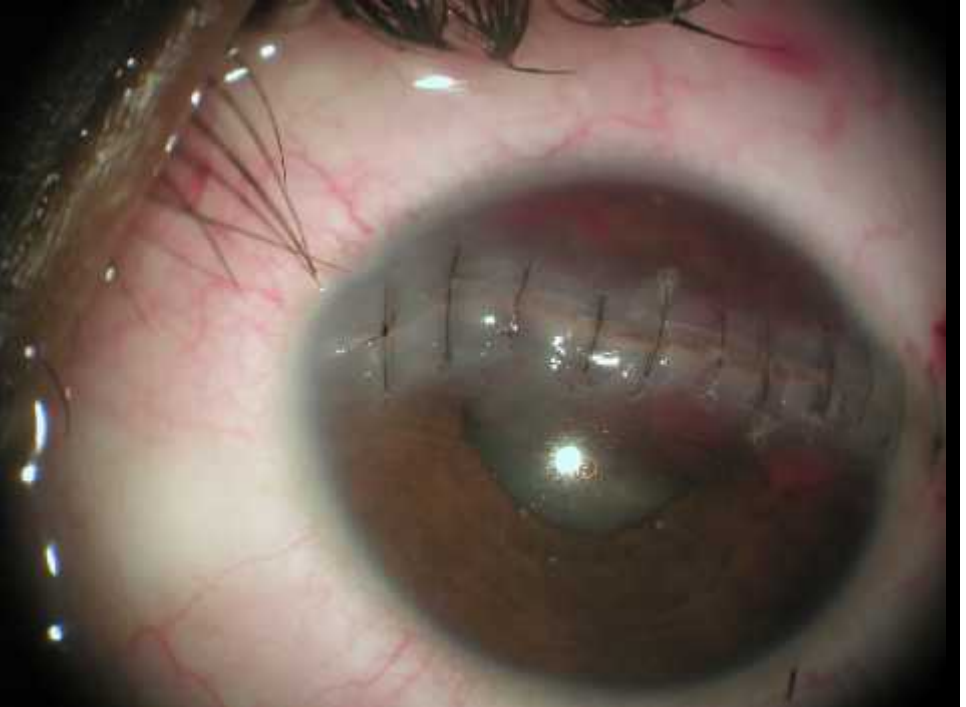
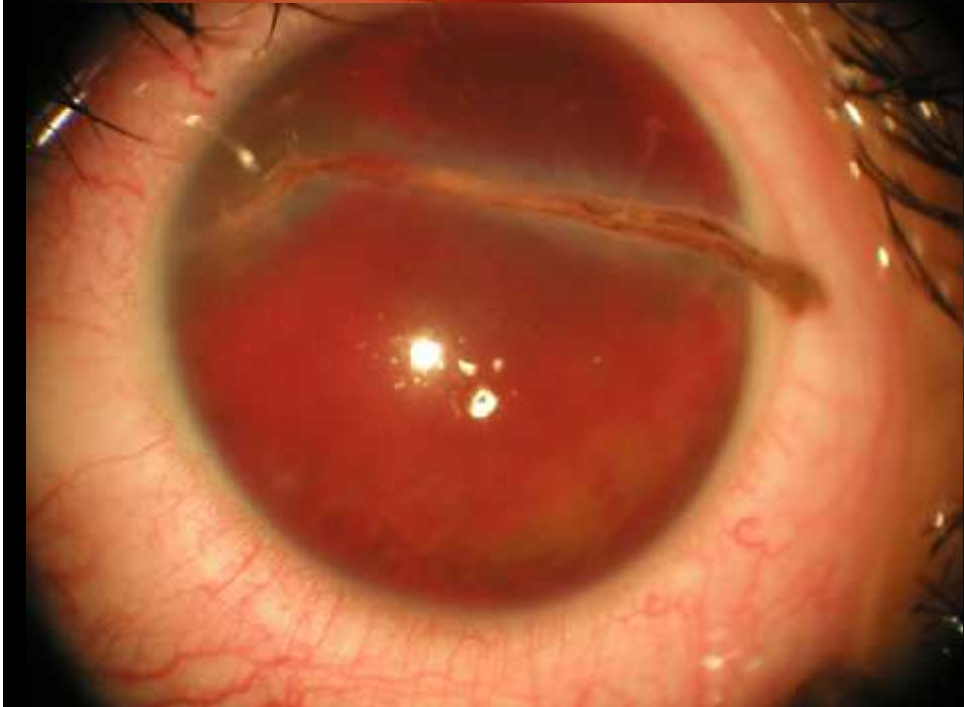
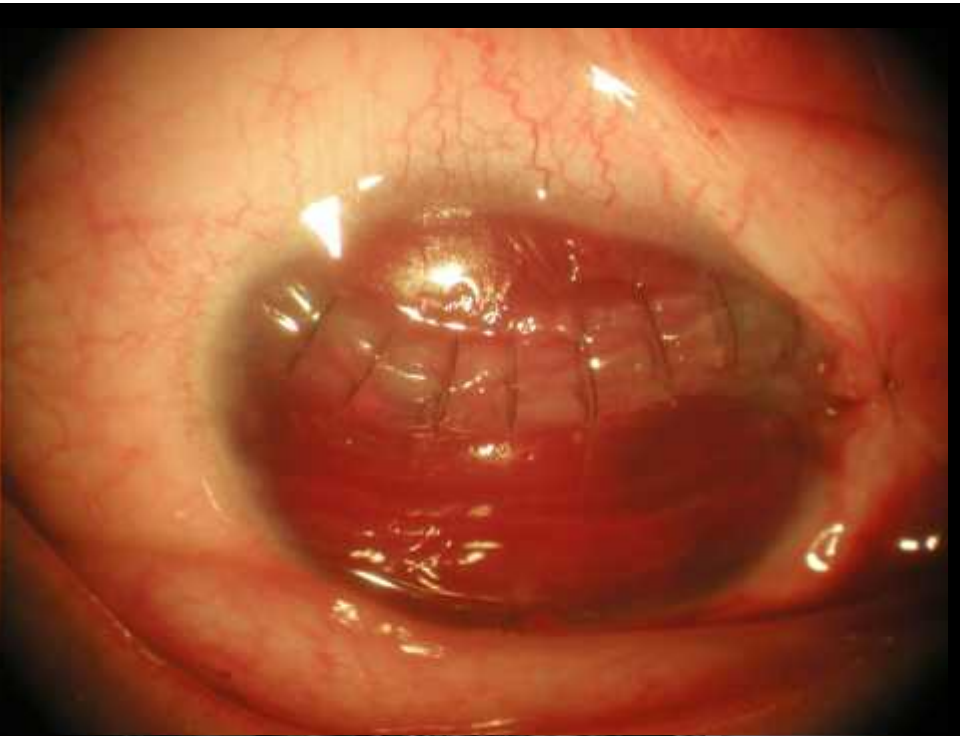
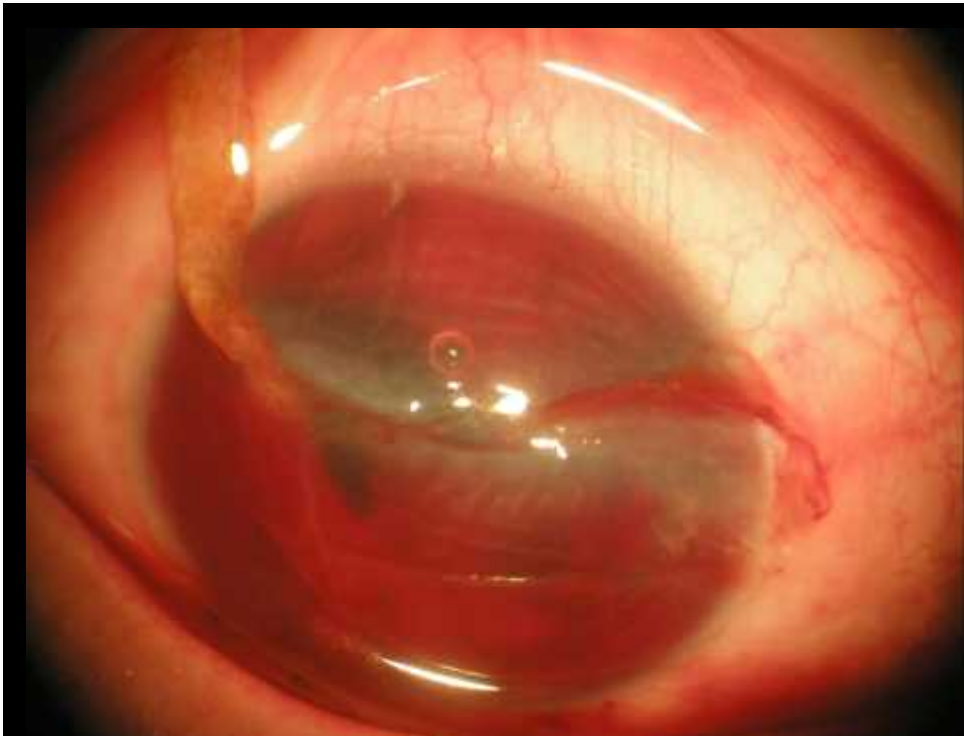


**НАРАНЯВАНИЯ НА
ОКОТО БЕЗ ЧУЖДО
ТЯЛО**





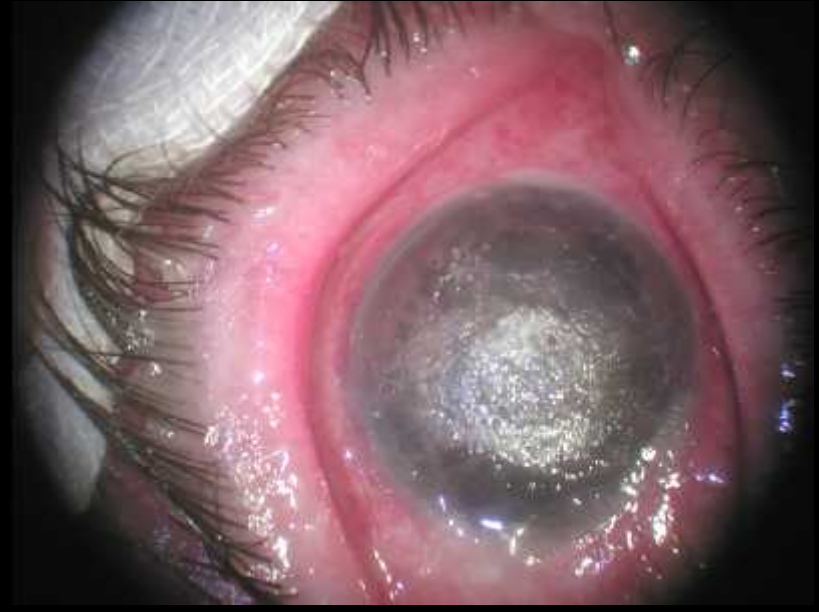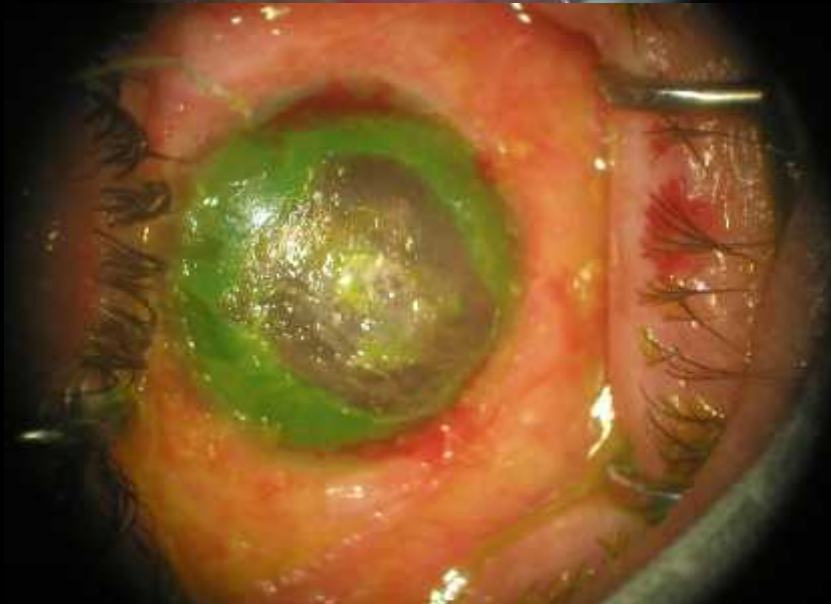

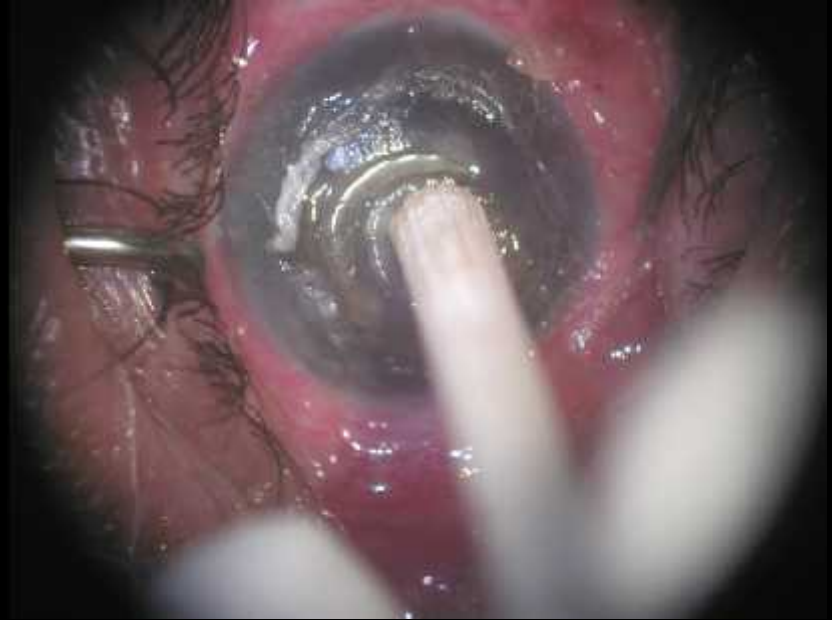
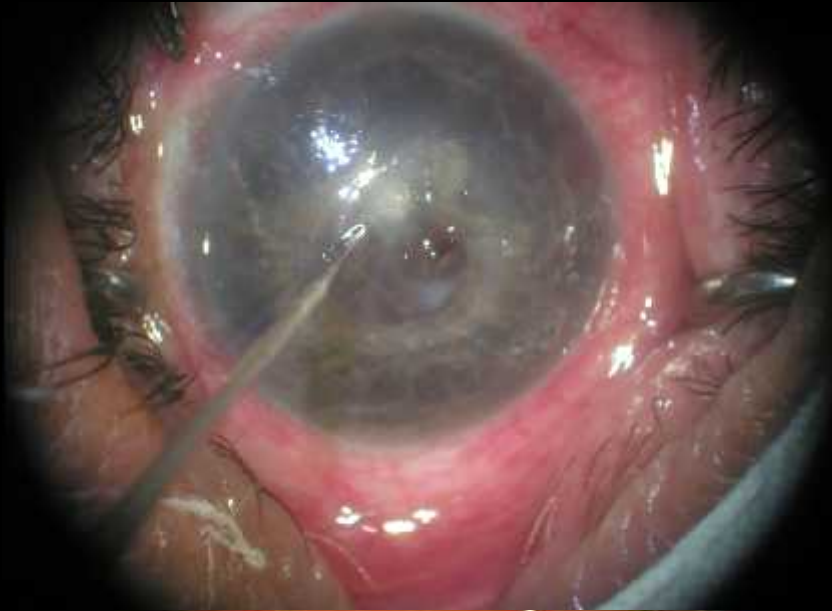

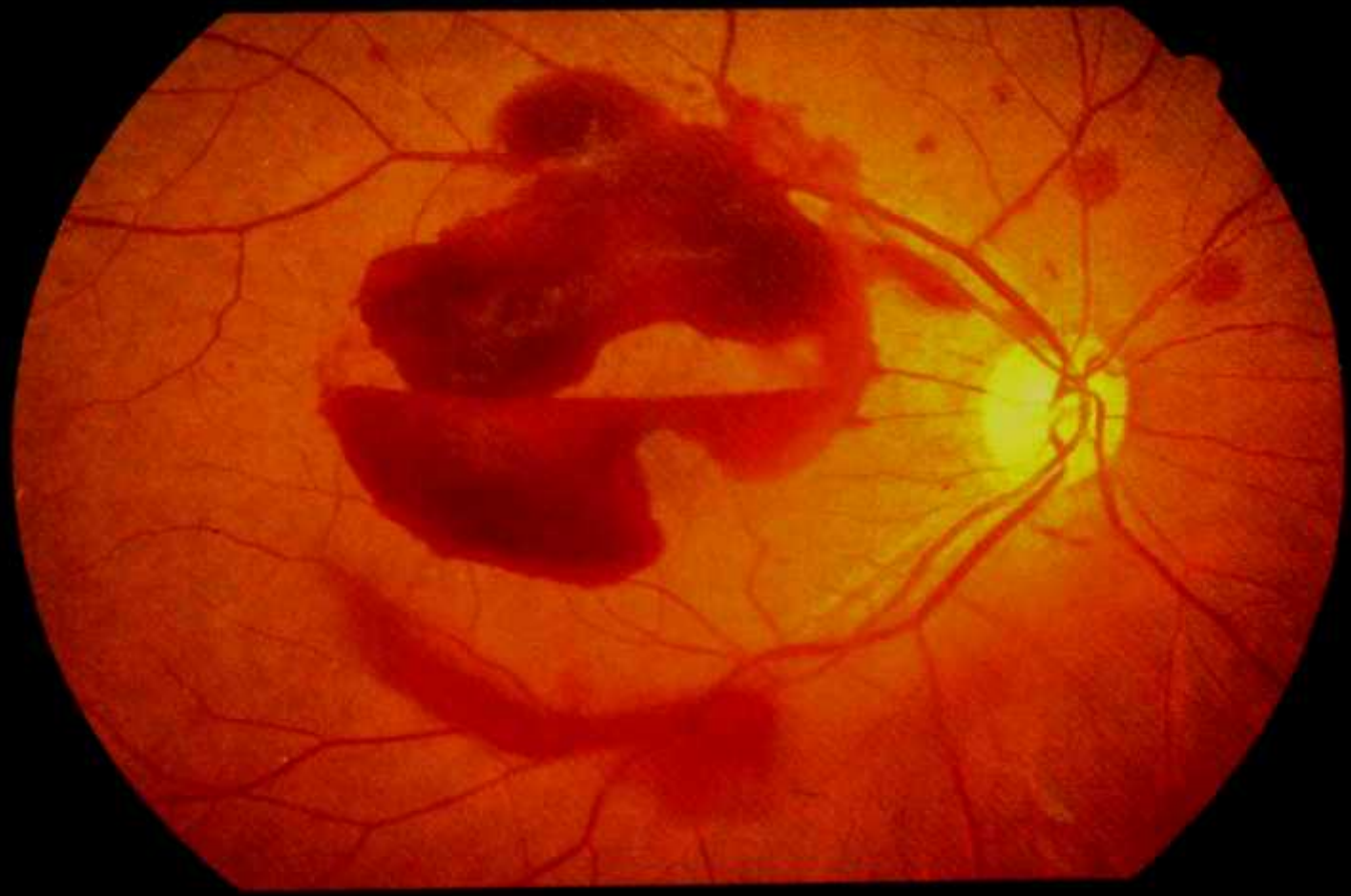-

”

“

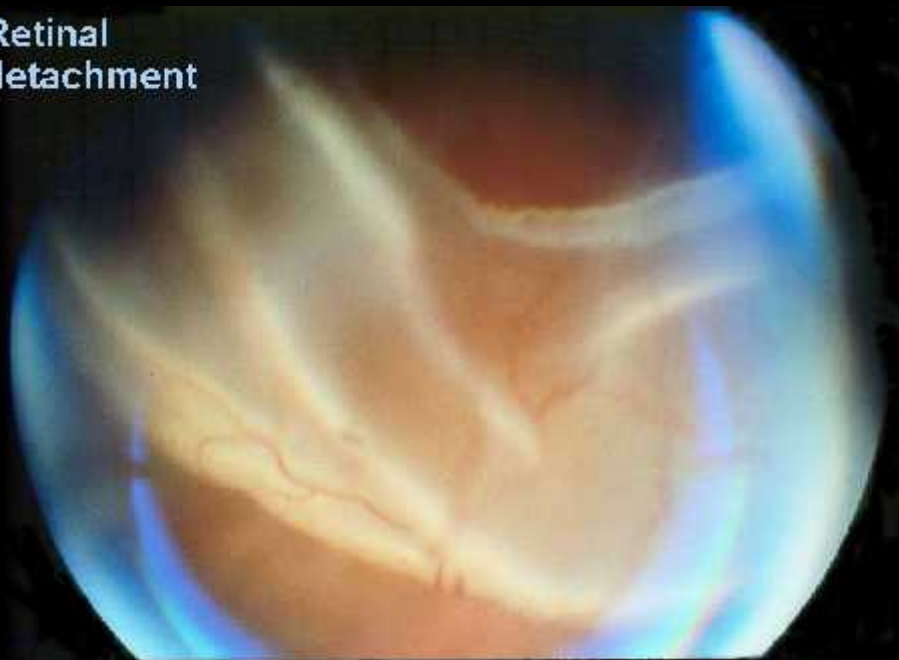

НАРАНЯВАНІЯ НА
ЗАДЕНІЯ ОЧЕН СЕГМЕНТ

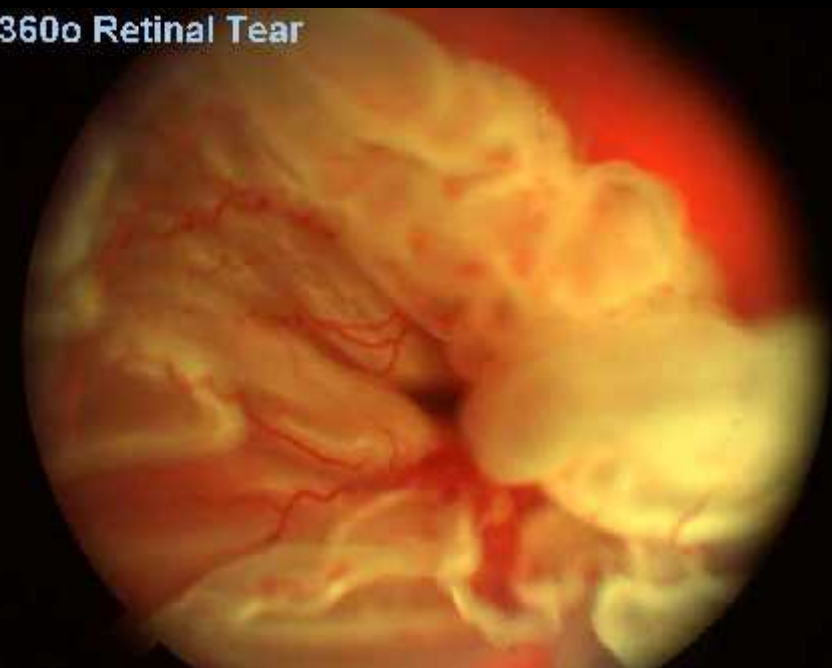


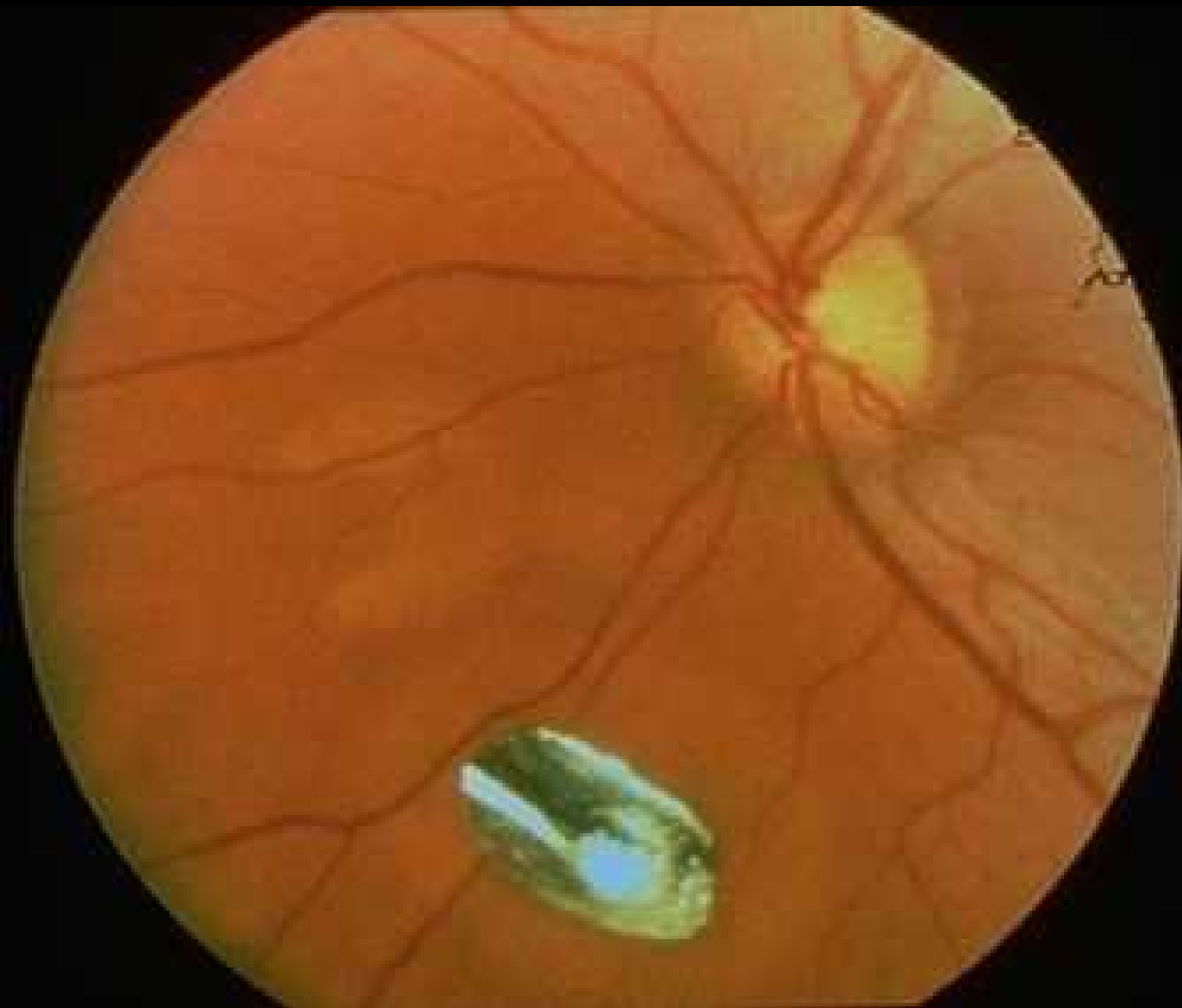
-

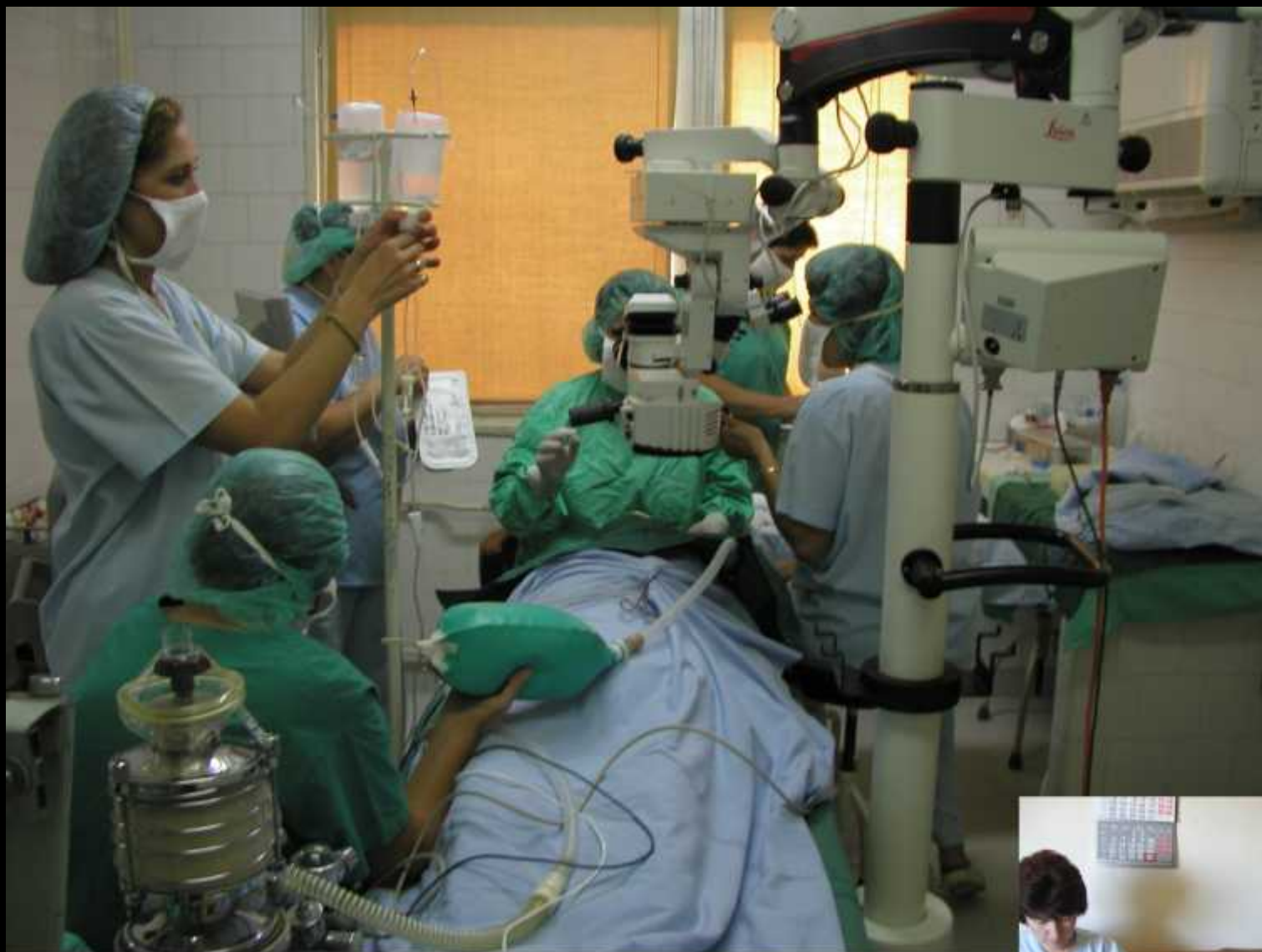Retinal detachment



360o Retinal Tear







Операционна - Очна клиника